

See discussions, stats, and author profiles for this publication at: <https://www.researchgate.net/publication/329254183>

Prosthodontic Solutions for Elderly Patients

Article · November 2018

CITATIONS

2

READS

1,707

6 authors, including:



Ramona Buser

Ludwig-Maximilians-University of Munich

20 PUBLICATIONS 485 CITATIONS

SEE PROFILE



Qin Yue

China-Japan Friendship Hospital

2 PUBLICATIONS 5 CITATIONS

SEE PROFILE



Patrick Zimmermann

7 PUBLICATIONS 6 CITATIONS

SEE PROFILE



Valerie Geraldine Anne Suter

University Bern, School of Dental Medicine

67 PUBLICATIONS 742 CITATIONS

SEE PROFILE

Some of the authors of this publication are also working on these related projects:



Oro-facial impairment in stroke patients [View project](#)




Single mandibular implant study (SMIS) [View project](#)

Prosthodontic Solutions for Elderly Patients

Ramona Buser, Qin Yue, Patrick Zimmermann, Valerie G. A. Suter,
Samir Abou-Ayash, Martin Schimmel



Dr. med. dent. Ramona Buser is a senior lecturer at the Department of Reconstructive Dentistry and Gerodontology at the University of Bern (Switzerland).



Dr. med. dent. Qin Yue is an ITI Scholar at the Department of Reconstructive Dentistry and Gerodontology, University of Bern, Switzerland (2017/2018). She specialized in

implant surgery and reconstruction at China-Japan friendship Hospital, Beijing, China in 2012 and was awarded a DMD, BDent by Peking University, School of Stomatology in the same year.



Patrick Zimmermann is a Master Dental Technician and co-owner of Zahnmanufaktur Zimmermann & Mäder AG, Bern. He specializes in advanced removable prosthodontics and full arch reconstructions.



Dr. med. dent. Valerie G. A. Suter is a senior lecturer and head of the section of Dental Radiology and Stomatology in the Department of Oral Surgery and Stomatology at the Uni-

versity of Bern. She is a board-certified oral surgeon as well as an ITI Speaker.



Dr. med. dent. Samir Abou-Ayash is a senior lecturer in the Department of Reconstructive Dentistry and Gerodontology at the University of Bern. He is a specialist in prosthodontics (DGPro) and implant dentistry (DGI).



Prof. Dr. med. dent. Martin Schimmel, MAS Oral Biol, is Professor for Gerodontology and Removable Prosthodontics in the Department of Reconstructive Dentistry and head of the Division of Gerodontology at the University of Bern. He has been an ITI Fellow since 2012.

ABSTRACT

With the so-called “baby boomer” generation reaching retirement, a new challenge in implant dentistry has emerged. Predominantly, tooth loss occurs later in life, accompanied by increased demand for partial dental prostheses. Edentulous patients are more difficult to treat due to advanced age, functional dependence, illness, and financial instability. Prosthetic planning becomes more complex as interindividual diversity increases with age. Considerations such as resilience, physical and mental status, medical history, and drug prescriptions must be individually assessed.

Treatment planning and restoration design should fulfill both functional requirements and esthetic demands. Prosthesis design should prevent further harm to the patient. This tertiary prevention approach should prevent local inflammation of the oral tissues, but also prevent secondary systemic infections, such as aspiration pneumonia.

There are many prosthetic options for partially or fully edentulous patients.

Dental technicians should be aware of the advantages and disadvantages of the various treatment concepts and materials, and contribute professional knowledge to the patient, dentist, and often third-party milling centers. Using CAD/CAM technology, customized attachments and prostheses can be individualized according to each patient’s requirements. Utilizing a combination of manual and digital production techniques, oral reconstructions can be rationally manufactured.

The duration of implant osseointegration remains unknown, but reports of up to 30 years’ follow-up are emerging. Hence, the environment of the implant – the patient – will change significantly, and implant restorations should be flexibly designed to meet the changing needs of an aging patient. This “back-off strategy” should be implemented, and prostheses should be continuously subjected to critical reevaluations and adaptation.

Keywords: Gerodontology, prostheses, edentulous, dental laboratory work

INTRODUCTION

The main focus of this article lies on elderly, partially dentate and edentulous patients with implant-supported or implant-retained reconstructions. Individual patient needs and how they are met are discussed, as are fabrication technologies, questions regarding choice of material, and the conceptual collaboration between the dentist and the dental technician. Ultimately, this article makes a case for modern reconstructive dentistry that offers a sophisticated treatment concept adapted to the needs of each patient. It intends to raise awareness of the variety and versatility of the available approaches.

At what age is an individual considered elderly or old? There is no hard and fast rule, as this question has a philosophical component in which medical, social, and

psychological factors play a role (Bürger 1960; Rowe et al. 1997). The natural process of aging is progressive and irreversible, and pathological changes may influence and accelerate the process.

The far-reaching consequences of the aging process are also felt in the field of dentistry. Physiological and pathological changes can affect teeth, nerves, muscles, and hard and soft tissues. Aging can thus influence the ability to chew, swallow, and interact as well as esthetics (Müller et al. 2016a). Poor chewing efficiency and/or pain related to teeth or dentures affect food intake, which may have consequences for general health (Schimmel et al. 2015). Missing teeth or poorly fitting dentures can have a negative effect on social interactions and self-esteem (Stenman et al. 2012). Dental care is an indispensable aspect of maintaining quality of life in old age.

Oral hygiene to maintain oral and general health is the primary goal in care for elderly patients. Well-designed and well-fitting prosthetic reconstructions of missing teeth are further important factors to restore function, esthetics, and quality of life. Whereas in former decades, prosthetic treatment for elderly patients meant in most cases full denture prosthodontics, the picture has changed in recent years. An increasing number of individuals retain their natural dentition until late in life, and the relative number of edentulous patients is decreasing at a high rate (Jordan et al. 2016; Schneider et al. 2017; Slade et al. 2014). However, the total number of elderly patients is increasing dramatically due to demographic changes; hence, edentulism is not likely to be eliminated in the near future. In the United States alone, it is estimated that 10% of the total adult population is edentulous, i.e. 32–35 million edentulous patients (Slade et al. 2014).

“Soft” factors when dealing with patients

Each member of the reconstructive team must naturally be familiar with the basics of partial and full denture prosthetics, static and dynamic load and occlusion, as well as phonetics. Equally important are the “soft” factors when dealing with patients that make personal contact with the patient advisable, if not indispensable. Here, it is worth considering some characteristics of the age group. Among these are possible difficulties associated with the loss of a partner, physical or psychological illness, use of medication, eating habits, or a change in the ability to adapt and react. Dealing with (older) patients demands empathy and understanding for their situation. Dentists and dental technicians should, therefore, periodically update their awareness of the basic tasks carried out by natural teeth, and the oro-facial system in general (Chen et al. 2012). Tooth loss leads to anatomical and morphological changes with which many patients have difficulty coping. Quality of life is restored only when patients are in possession of a functional prosthesis tailored to their individual needs.

Meeting high expectations

The expectations of young-old patients, the so-called baby boomers now reaching retirement age, has increased with respect to the quality, function, and esthetics of their prosthetic restorations. We are currently observing the transition from one generation of older patients – the post-war generation – to the next – the baby boomers (Schimmel et al. 2017a). The latter are accustomed to a high level of service from dentists and dental technicians that they do not intend to forego as they grow older. Many older people are looking for an esthetic restoration that looks perfectly natural (Fig. 1). As a result, a stronger focus on implant prosthetics is developing in the rehabilitation of elderly patients. Implant therapy renders various therapy options possible to edentulous patients – from simple and functional to functionally and esthetically high-end solutions. In order to provide this kind of restoration, dental technicians need detailed knowledge of the positioning of prosthetic teeth, materials, and function as well as of the above-mentioned soft factors. They must also understand how these individual aspects interact, and appraise the significance of the restoration to the patient.

Regrettably, the manufacture of removable partial and full dental prostheses is frequently given little attention by the dental laboratory. What is achieved to perfection by dental technicians in other areas such as fixed restorations, should also be a matter of course for removable prostheses. This is where priorities need to be set in an age cohort in which up to 50% wear removable dental prostheses (RDP) (Schneider et al. 2017). Highly qualified dental technicians are needed within the treatment team that looks after partially dentate and edentulous patients in order to assist in finding the single optimal choice from the variety of restoration options available. As both the complexity of reconstructive work and average patient age continue to increase, one person needs to take the lead and maintain an overview of the entire process. This influences communications between the dentist, patient, and dental technician in which digital channels of communications are playing an increasingly greater role.

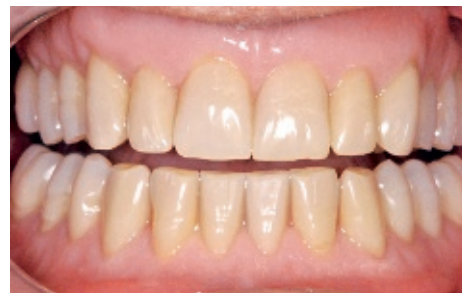

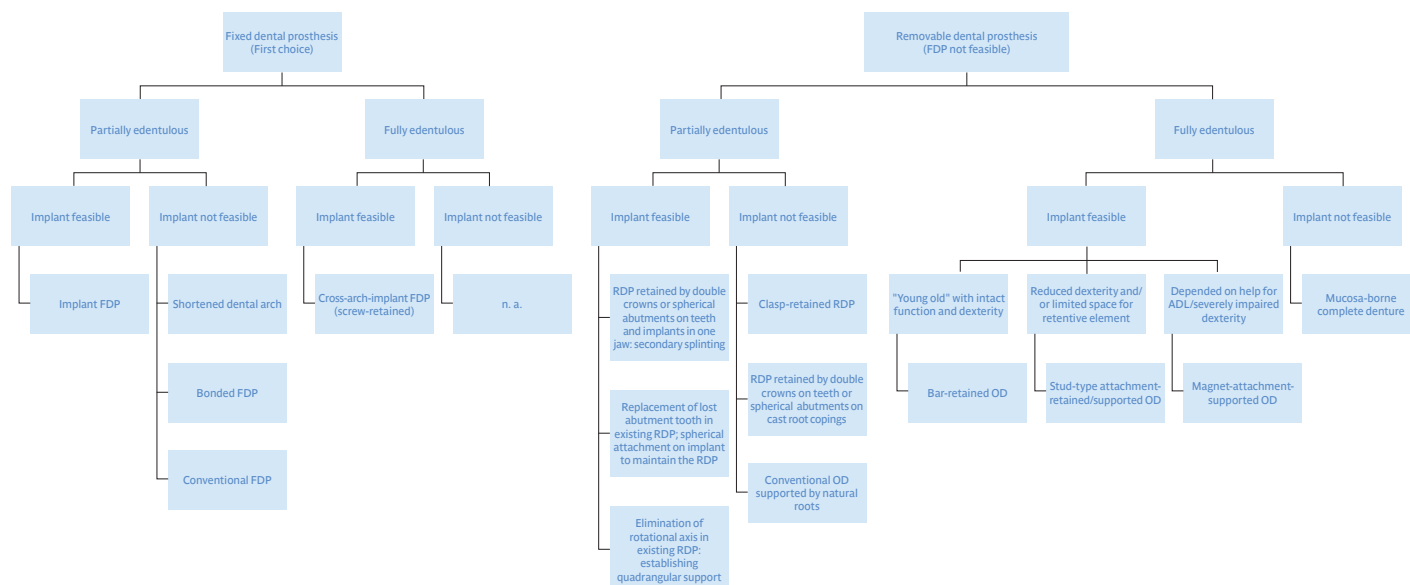
Fig. 1: Not only younger but also many older people have no desire to be seen wearing clearly identifiable dentures – the demand is for a prosthesis that mimics natural dentition, as shown here with overdentures in both jaws

SELECTING THE RESTORATION CONCEPT

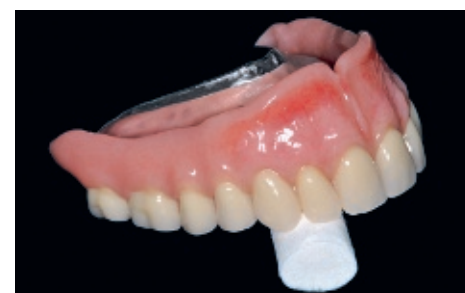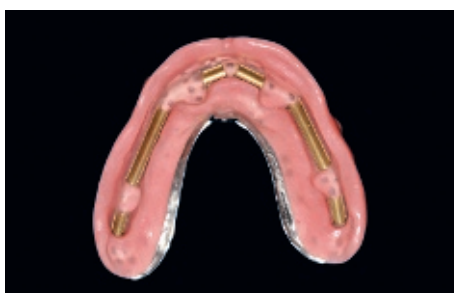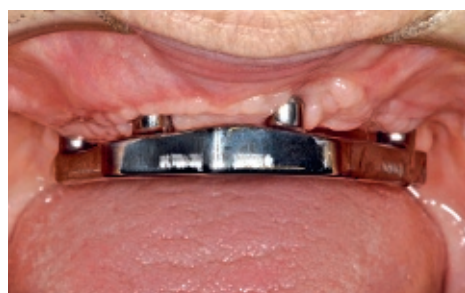Implant-supported restorations

Implant therapy is a thoroughly investigated approach for restoring partially dentate and edentulous patients. Treatment planning is managed by a team of professionals. Age-related factors, such as multimorbidity, manual dexterity and potential limitations thereof, as well as reduced adaptability are included as part of the process. It should be considered that the restoration may need to be modified at a later date to account for diminished strength and dexterity of the hands and/or other co-morbidities, including cognitive impairment. With increasing multimorbidity, it should be possible to revert to a prosthesis that is easier to handle in order to facilitate hygiene care for nursing staff if necessary (Müller et al. 2013). In addition, the individual needs of the patient, as well as general health and financial means must be considered during treatment planning. Ultimately, subjective factors and individual adaptability are key to the success or failure of prosthetic therapy.

The initial decision is whether to opt for a fixed or removable solution (see flow chart). In addition to oral comfort, hygiene plays a role here. As long as a few basic principles are followed, an implant-retained removable prosthesis facilitates oral hygiene (Figs 2a–c). If a fixed solution is selected, it must be designed with accessibility for oral hygiene.



Flow chart to illustrate prosthodontic treatment options for the elderly patient. The most important decision is whether to plan a fixed (FDP) or a removable dental prosthesis (RDP); RDPs should only be planned if the restoration with FDPs is contraindicated, e.g. when the patient is no longer as resilient to extensive dental treatment, cannot maintain correct oral hygiene or the dental/general prognosis is doubtful. Overdentures (OD) retained or supported by natural teeth provide better tactile sensitivity than implant-supported ODs, but abutment teeth may develop caries or periodontal problems



Figs 2a–c: Depending on the indication, a removable implant-supported, bar-retained prosthesis is recommended for edentulous patients. It can be cleaned more easily than fixed full arch prostheses, but is still extremely stable. Labwork mundwerk dental (Bern)

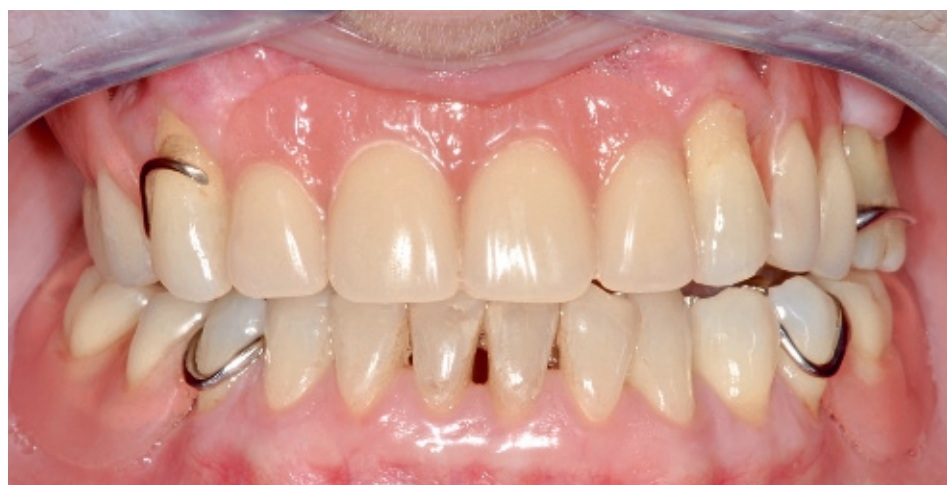

Fig. 3: Where abutment teeth are available, the clasp-retained denture represents a cost-efficient option

Clasp-retained dentures

In addition to classic crown or bridge restorations, removable devices are frequently provided for patients in the third and fourth phase of life. For financial reasons, clasp-retained dentures are often the first choice for partially dentate patients. The aim is to have as few clasps as possible and as many as necessary to establish an equilibrium between damage and benefit from the metallic structures. N.B.: 5-year survival rates were reported to be as low as 86.6% for direct abutment teeth (Tada et al. 2013). If the abutment teeth are favorably distributed and provide appropriate support, two clasps are sufficient (Budtz-Jorgensen et al. 1995) (Fig. 3). The restoration should be designed to facilitate repair if further teeth are lost. The palatal plate has an advantage

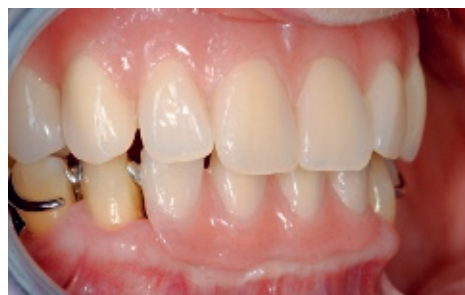

Fig. 4: Clasp-retained restorations often fulfill esthetic requirements, even in the anterior mandible. The amount of metal should be kept to an absolute minimum; two clasps normally suffice

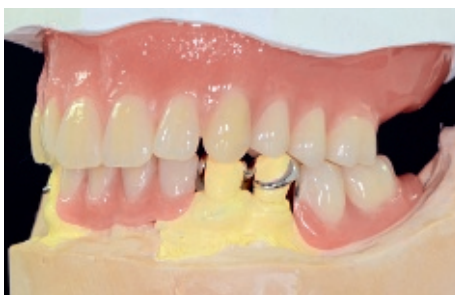

Fig. 5: The distribution of abutment teeth in the lower jaw at the front and side allows for clasp-retained prostheses

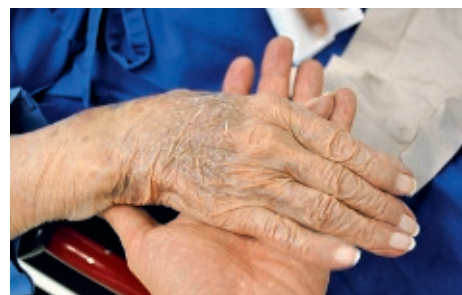

Fig. 6: Design and retentive force of an implant overdenture should be adapted to the patient's individual capacity. Therefore, the dental team should increasingly pay attention to "non-dental" planning factors

over the bikini design in terms of force distribution and when transitioning to a full denture, but is sometimes not well tolerated by patients. Here too, the periodontally and interdental open design of the structure is very important to allow for good oral hygiene even in old age (Budtz-Jorgensen 1999) (Figs 4–5).

Age- and function-oriented dental care concept

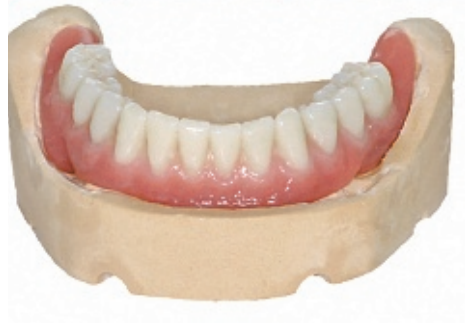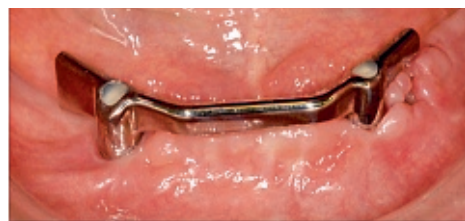We recommend an age- and function-oriented care concept – this also applies to implant-supported overdentures. At the School of Dental Medicine of the University of Bern, we follow a graded approach of implant prosthetics that is adapted to the manual strength and dexterity of the patient

(Fig. 6). Given that the implant's success is to be secured, if possible, for the remainder of the patient's life, implant treatment must therefore be aligned to whether the patient can autonomously insert, remove, and clean the restoration (Müller et al. 2016b). Additionally, it must also be possible to remove the restoration. Two-piece implant-abutment retentive elements are preferred on the shortest and smallest implants possible that will still assure long-term function under masticatory forces. This will reduce invasiveness and morbidity during the treatment's surgical phase. Ideally, implants should also be retrievable or easily put to sleep, if adequate care can no longer be assured (Schimmel et al. 2017a).

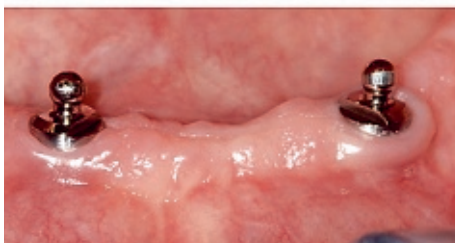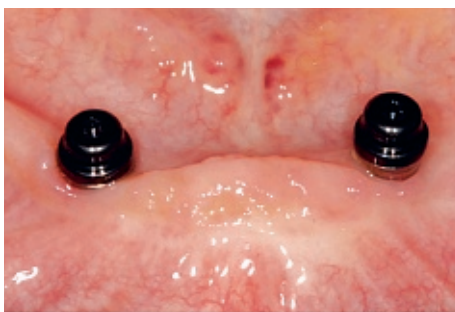We design our implant prosthetic concept for edentulous patients according to the McGill consensus and a functional classification for completely edentulous patients. These concepts should only be applied if the IOD is opposed by a complete mucosa-borne prosthesis, otherwise a higher number of supporting implants should be discussed (Fig. 7):

- for young-old people: maximal rigidity via a bar restoration. Typically a milled bar on two tissue-level implants with distal extensions (max. 7 mm)
- when there are vertical space constraints or potential difficulties cleaning a bar restoration: stud-type attachments like the Novaloc™ anchor (Straumann, Basel/Switzerland)

Standard bite force



Space requirements hygiene



Dexterity frailty

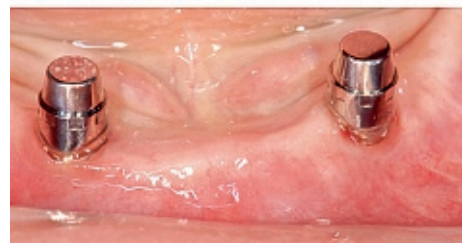
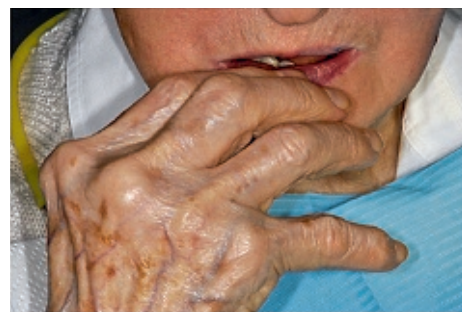
Fig. 7: At the University of Bern a phased approach is followed for edentulous patients, depending on anatomy and functional capacity. We prefer two-piece implants placed with minimally invasive surgery and adapted to co-morbidities. The length and diameter should be as small as possible, but as large as necessary

Attachments for Complete Implant Prostheses

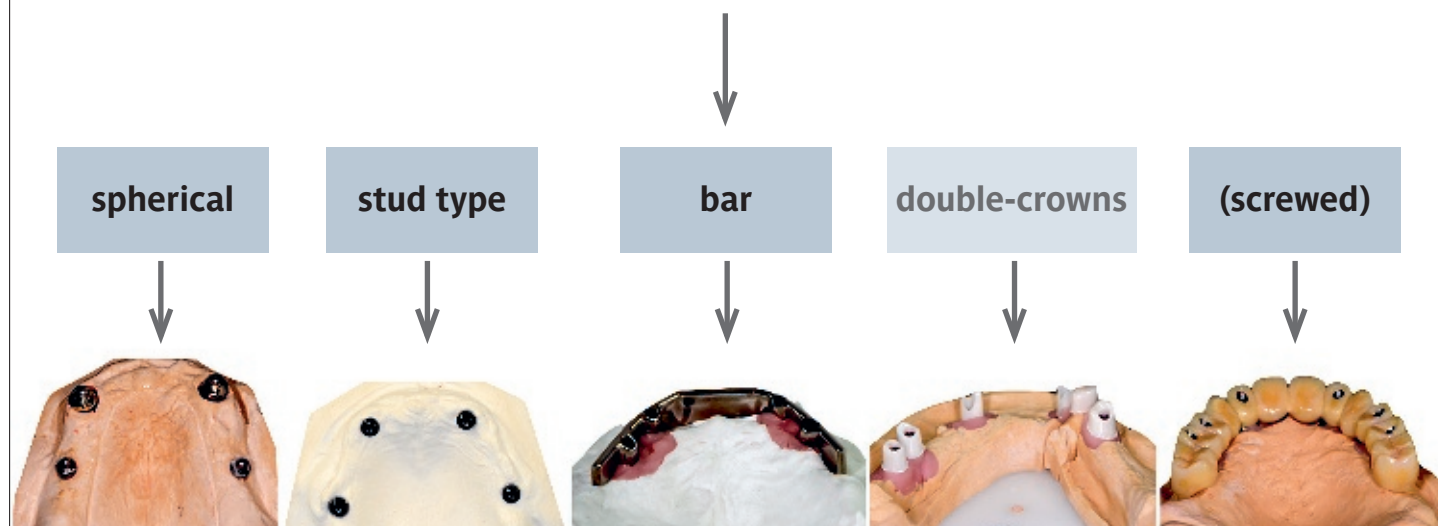
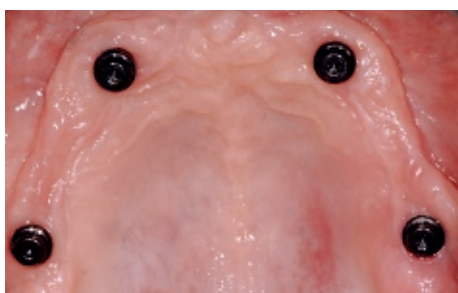


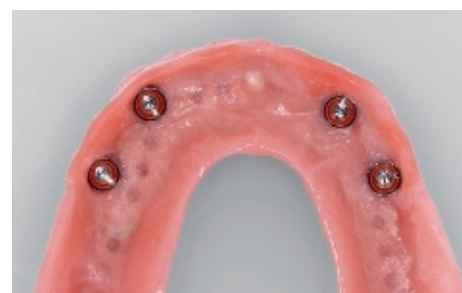
Fig. 8: Examples of anchorage

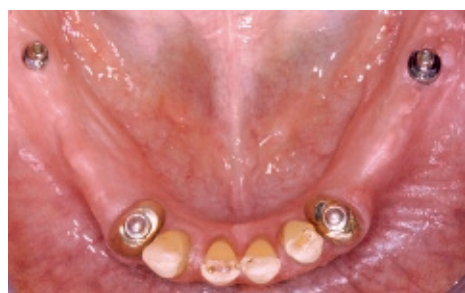

Fig. 9: Distal implants in implant-assisted overdentures help to avoid a rotational axis by establishing quadrangular support. This reduces movement of the denture under function and improves the prognosis of the abutment teeth



Figs 10a–b: Straumann Novaloc-retained removable prosthesis without a palatal plate where space is too limited for primary splinting. At least four implants are indicated



- for patients with nursing care requirements and/or severely reduced dexterity: magnets (e.g. Titanmagnetics K-Line, steco, Hamburg)

Examples of tooth- and implant-supported restorations

Restorations can be retained in a variety of ways and we select the approach on a case-by-case basis (Fig. 8).

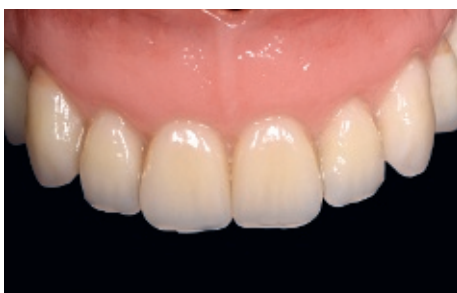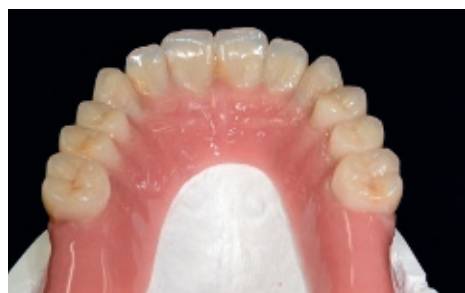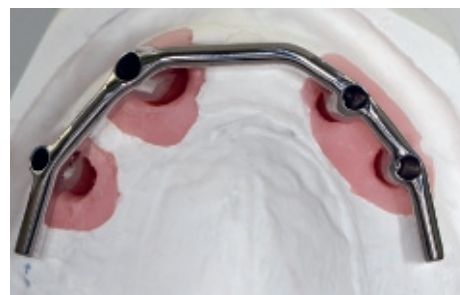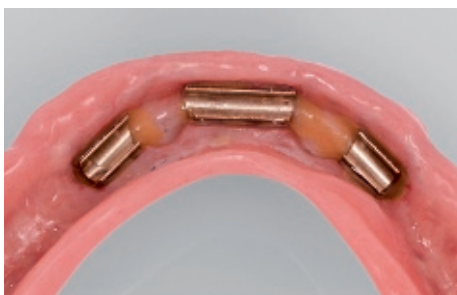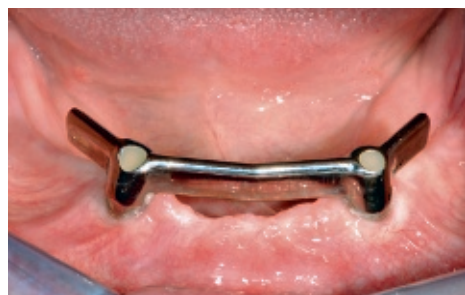Spherical abutments with residual dentition (removable prostheses)

In Switzerland, a method frequently applied following root canal treatment is the use of cast root caps with soldered spherical or Gerber attachments. Given the correct

indication and treatment, this treatment modality shows good survival of anchor teeth and prostheses (Mercouriadis-Howald et al. 2018). When used in combination with implants, they offer patients a securely retained removable restoration (Fig. 9). This option is a relatively simple, implant-supported solution, particularly in terms of after-care. In just a few easy steps, the retention force (e.g. DalboPlus anchor, C+M, Biel, CH) can be increased or the retentive part replaced. If it needs to be extended, an additional anchor can be easily integrated into the existing prosthesis. If an abutment tooth is lost, an implant can be placed in the same position and the well-adapted prostheses can continue to be used.

Stud-type anchors (removable prostheses)

For edentulous patients, it is recommended to retain an overdenture with at least two implants in the mandible and four in the maxilla. However, a recent review found evidence that four or six implants should preferably be placed in the mandible and maxilla, respectively (Kern et al. 2016; Schley et al. 2013). The actual retention element consists of a stud-shaped retention part and a transmucosal cuff (Figs 10a–b). While the male part serves as the implant abutment, the female retentive element is incorporated into the base of the prosthesis. Impression-taking is sometimes challenging due to space requirements – the prosthesis must be milled out generously. An example of



Figs 11a–e: The bar-retained prosthesis supported by two implants in the severely atrophied lower jaw is the solution of choice at ZMK Bern if the maxilla is fitted with a conventional complete denture and the patient is able to clean the bar. Similar to panels (a) and (b), a bar-retained prosthesis is also possible in the maxilla, however, with at least four implants. Through a relatively easy procedure, patients have the benefit of a very stable prosthesis. The limitations of the anterior palatal area must, however, be taken into consideration

modern retention systems is the Novaloc™ attachment (Straumann AG, Basel) (Schimmel et al. 2017b). The retention force is individually set via the retention caps so that the patient can handle the prosthesis him- or herself. This must be clinically tested, as manual strength is often overestimated. Another challenge comes with reline impressions: we always remove the housings before the impression, as stud-type attachments are very sensitive to even subtle changes in height. Alternatively, the housings can be secured with a direct technique, which promises the best clinical results.

Bar retention (removable prostheses)

In this era of CAD/CAM technology, we can mill highly individualized bars and could manufacture the bar clips with electroplating techniques for optimal results. However, given financial constraints and the demand for easily manufactured/maintained designs, the goal should be simplicity. Experience with the CAD/CAM-fabricated titanium parallel Dolder bar with distal extensions has been very positive at the University of Bern for many years (Fig. 11a) (Katsoulis et al. 2011).

At least two implants are required in the mandible and four or more in the maxilla (Kern et al. 2017); other concepts are still

experimental with high rates of complications (Zembic et al. 2017). The implants are primarily splinted via the parallel-milled bar, also enabling the use of short implants in the maxilla. The minimum length of the retentive bar should be 20 mm to allow for adequate retention and horizontal stability.

One should bear in mind that the minimum height of the bar in the maxilla can significantly affect speaking. A minimum of 12 mm space from implant neck to incisal edge is recommended (Phillips et al. 2001), and an offset of 2 mm between the apical side of the bar and the mucosa has proved clinically valuable in maintaining correct hygiene and avoiding hyperplasia (Fig. 3a). Further attention should be given to not blocking the anterior third of the palate with the bar-overdenture, where the tongue forms consonants like “s”, “l”, “t” or “n”. If there is still a large amount of alveolar bone present, either another retention system must be chosen, or sufficient osteoplasty must be performed during implant surgery.

The bar is milled out of a solid block of titanium or CoCrMd alloy with increased stability relative to soldered gold bars, allowing for non-linear geometries that help respect functionally important anatomical areas, like the anterior third of the palate or the floor of the mouth. Also, there is no

necessity for additional abutments, which helps to reduce costs and avoid potential technical complications.

Ideally, diagnostic steps for a bar-retained overdenture comprise a diagnostic set-up with critical appraisal of the available vertical and horizontal space. This is especially true for maxillary implant overdentures.

To anchor the milled bar, we prefer the appropriate pre-fabricated Dolder gold clips (C+M, Biel, Fig. 11b). These can be easily activated and deactivated and show very reliable retention over a long time (Kobayashi et al. 2014). Finally, the overdenture is finalized (Figs 11c–e); both pink and white esthetics can be individually adapted as desired. This therapeutic approach has many functional advantages and is well accepted by patients.

Double-crown retained prostheses (removable prostheses)

Double-crown, e.g. telescopic-crown, retained prostheses represent a valuable form of treatment with many advantages; for example, they can be easily converted, extended, and repaired, and are suitable for patients with limited manual dexterity. In addition, they allow the combined use of both natural dentition and implants in one jaw. There is now a wide variety of ma-

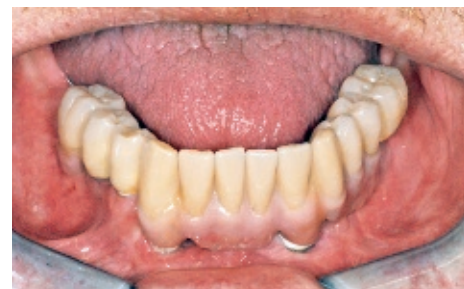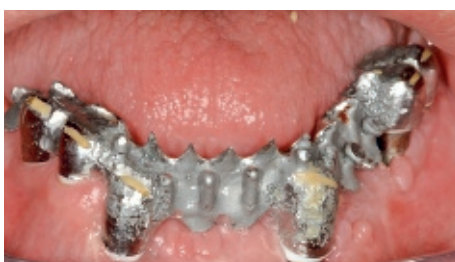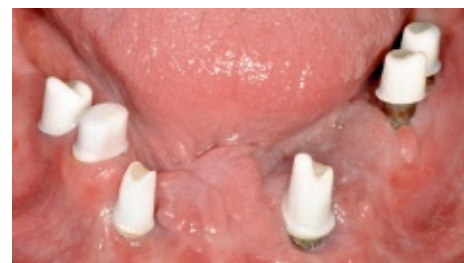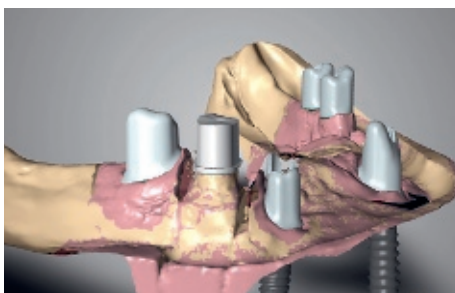
materials suitable for use with this indication, but only a few material combinations are well documented. The standard of care remains gold primary and secondary abutments, cast and electroformed, respectively. Another popular combination is zirconium dioxide primary with electroformed secondary crowns. Several recent reports also describe a complete CoCrMd primary-secondary-tertiary system (Kurzrock 2017). Modern subtractive and additive CAD/CAM manufacturing techniques are now expanding the horizon to a variety of new materials, e.g. PEEK or PEKK. However, only when long-term clinical experience is available will we know how these materials tolerate sustained use. One disadvantage is the high cost of manufacturing and the combination of various materials, although CAD/CAM technology (from milling to selective laser melting) promises lower costs in the future (Figs 12a–d).

Simple reconstructions using implants (fixed removable)

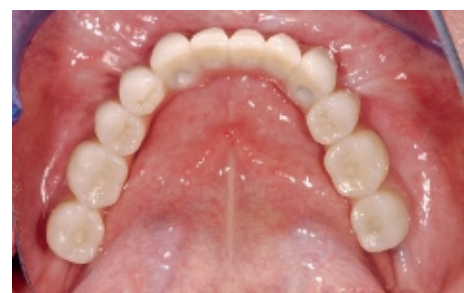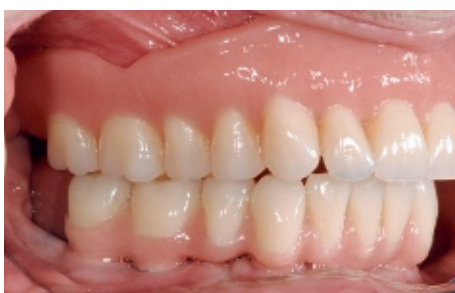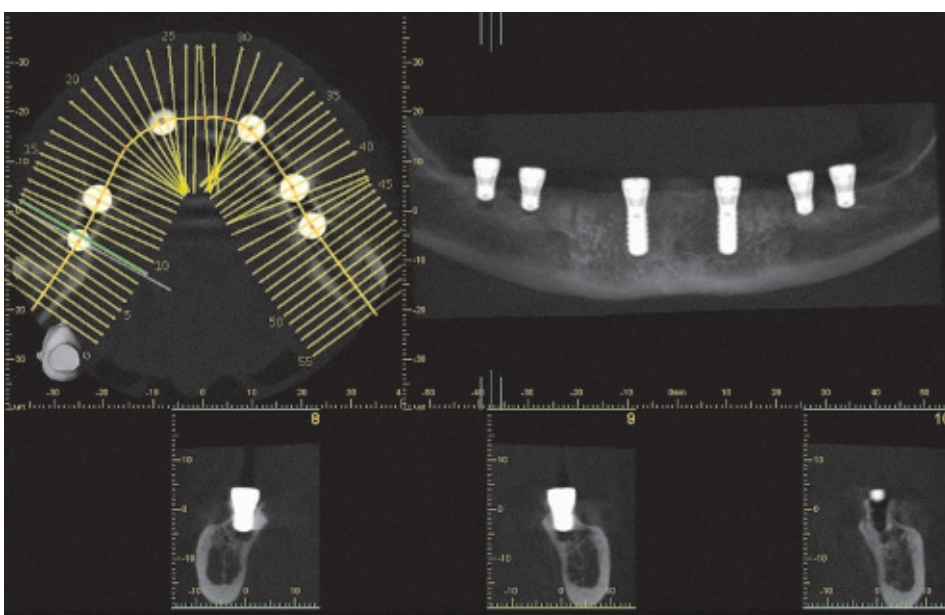
An efficient approach to fixed restorations for edentulous patients is the Straumann Pro Arch concept. This concept is the subject of an ITI-supported study at the Department for Reconstructive Dentistry and Gerodontology (ZMK Bern) and Queen's University Belfast, Northern Ireland. Patients receive four or six implants in the edentulous mandible on a randomized basis. Standard tissue level implants with a minimum length of 8 mm are used interforaminally. Ultra-short (4 mm) tissue level implants are used for posterior support. The idea behind this approach is to provide a fixed implant-supported prosthesis without inserting long implants at an angle or having to perform bone augmentation. Furthermore, it is often possible to avoid time-intensive and costly bone augmentation procedures. In addition, it would be easy to remove the four posterior implants should it be necessary to “downgrade” to an overdenture when the patient can no longer clean or handle the prostheses at an advanced age (Figs 13a–c).

Oral hygiene

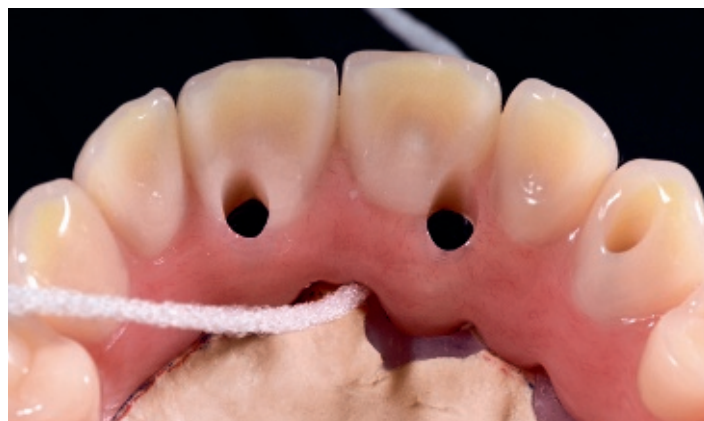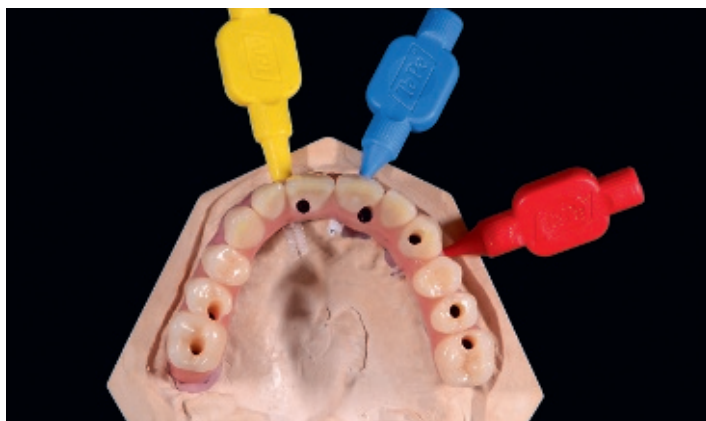
When planning prosthetic implant therapy, the top priority is to facilitate oral hygiene. In this regard, removable prostheses have a clear advantage over fixed prostheses.



Figs 12a–d: Clinically demanding situations, as with the tumor patient shown here, can be handled efficiently using CAD/CAM technologies



Figs 13a–c: Bone augmentation procedures can often be avoided by using the Straumann Pro Arch concept, even for fixed cross-arch prostheses. It is currently being investigated in a clinical study at the ZMK Bern, supported by the ITI Foundation



Figs 14a–b: Facilitated oral hygiene is a crucial component of geriatric dentistry. The restorations shown here are very demanding of patients and should only be realized in this form if the patient is still able to handle fine oral hygiene tools

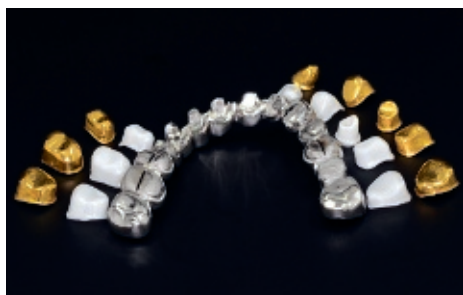

Fig. 15: Dentistry today is characterized by the variety of materials available – this demands a broad knowledge of materials on the part of the dental technician

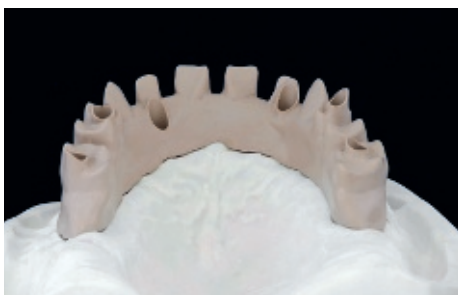

Fig. 16: New machine-processable materials, such as PEEK or PEKK, are accompanied by new characteristics that must, however, prove themselves over time

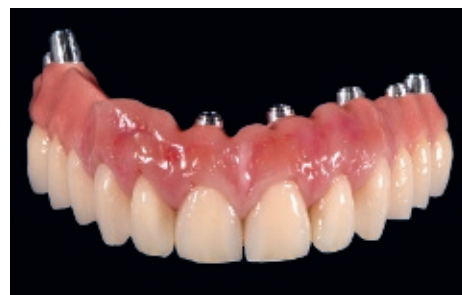

Fig. 17: Implant-supported fixed hybrid prostheses in a case with advanced resorption Cawood IV

With patients whose manual dexterity is limited, unsplinted retaining elements (e.g. spherical attachments, or Novaloc™) are preferred. If oral hygiene can be assured by the patient, family, or nursing staff, an implant-supported bridge or bar-supported overdenture is possible, supported by a minimum of four implants. Space for cleaning must be ensured when designing fixed restorations (Figs 14a–b).

Materials

A great deal has changed in recent years with regard to materials for removable prosthetic restorations. The use of CAD/CAM technology allows for the use of numerous innovative materials (Fig. 15).

All-metal frameworks

The history of porcelain-fused-to-metal crowns is documented in detail. In addition to casting, frameworks are now also produced via machine milling and additive

fabrication by means of laser sintering on a powder bed.

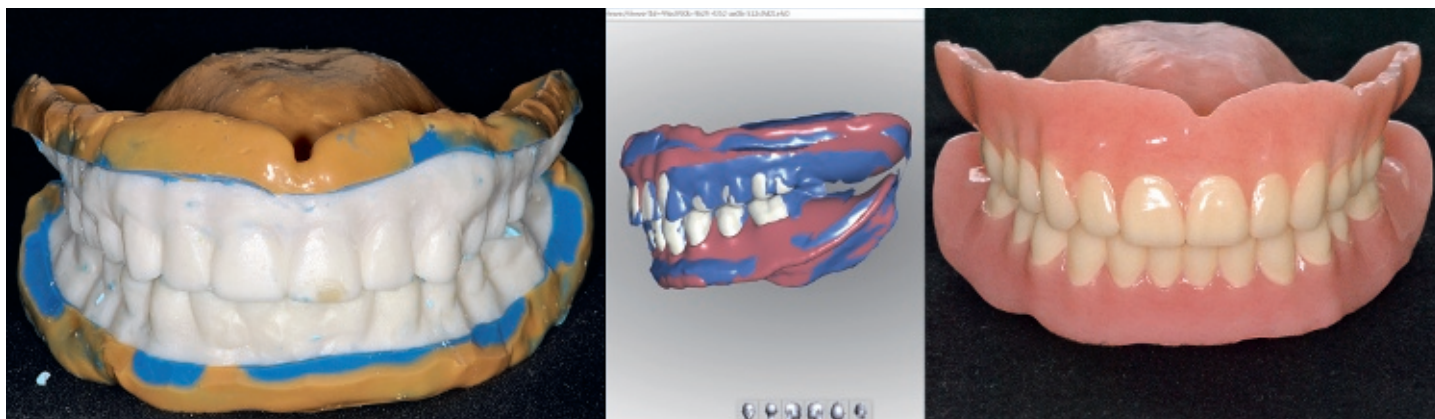
Metal-free frameworks

All-ceramic restorations on a high-strength zirconium-oxide framework have also become accepted as reliable. These offer an excellent fit thanks to CAD/CAM manufacturing processes. The current focus for framework materials is on high performance polymers that are generally thought to present many advantages. There is, however, a significant disadvantage that should be considered. To properly enable oral hygiene, restorations must be designed to allow easy cleaning (self-cleaning, inter-dental spaces for the inter-dental brush). Designing the framework to fulfill this need involves maintaining the distance to the gingiva, which can be difficult when using PEEK or PEKK. The materials' characteristics make it difficult to maintain adequate dimensions for the framework. If this can be achieved,

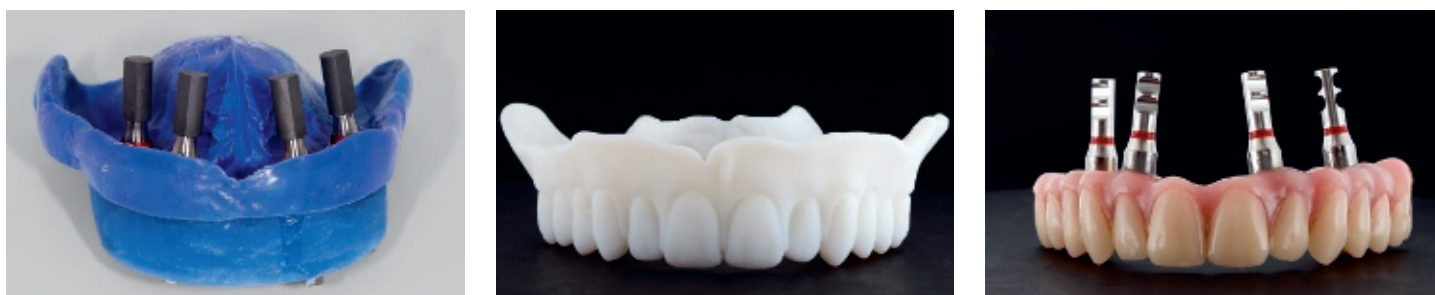such polymers could be suitable for use in implant prosthetics (Fig. 16). The material has a certain elasticity, and is adaptable to a certain point compared to high-tensile material (Silla et al. 2016).

Esthetic finishing

According to the indication and the patient's wishes, lithium disilicate, zirconium dioxide, composite resins, or preformed teeth can be used for esthetic finishing. Once again, a customized restoration concept in combination with the needs of the patient are the primary points of consideration (Zimmermann et al. 2016). From experience, we know that wear must be taken into consideration when working with composites and/or synthetic teeth (Fig. 17). Pronounced wear leads to loss in the vertical dimension, accompanied by reduced chewing function. In such cases, depending on the load, the teeth must be replaced after several years (Balshi et al. 2016).



Figs 18a–c: Example of cost-effective option with a computer-aided workflow: complete copy denture using the AvaDent system. More processes are needed for the elderly patients of today and tomorrow that are light on the wallet and enable a more than adequate quality of life



Figs 19a–c: The AvaDent system allows a complete denture to be transformed into a fixed supraconstruction by means of digital duplication techniques

“Digital dentistry” for aging patients

Using new concepts, we are able to offer a variety of therapeutic options to patients in their third or fourth life phase. Digital solutions for the edentulous jaw are particularly patient-friendly; for instance, when using the digital workflow, depending on the situation and system, the number of appointments can be reduced (Schimmel et al, 2016). For example, patients who are very advanced in age often have difficulty getting used to a new prosthesis. In this instance, we can (e.g. using the AvaDent system, Global Dental Science Europe, Tilburg, Netherlands) simply copy the old prosthesis and use it as the basis for a new set of dentures (Figs 18a–c). Similarly, if a set of dentures is lost, it can be reproduced within a short time at no great effort.

It should also be noted that it is now possible to produce bar- or screw-retained implant-supported prostheses without

a model following a completely digital workflow (Figs 19a–c).

CONCLUSION

Many questions in implant dentistry remain unanswered as we face a rapidly aging society and frequently see patients who are advanced in age. Will patients be able to afford an implant-supported prosthesis? Are the boom years of well-funded pensions over? How will increasing life expectancy and the current discussions regarding pension funding be addressed (McKenna et al. 2015)? Already today, many older patients whose quality of life depends on a good prosthesis can only finance it thanks to financial support from third parties. Cost-efficient options will be required when moving forward. As in every other area of prosthetic dentistry, the edentulous patient should have the possibility to choose

between various treatment options without having to sacrifice reconstruction quality. Whether the optimal solution involves removable complete dentures, a removable implant-supported prosthesis, or a fixed prosthesis, this area is an important component of reconstructive dentistry and should be given sufficient attention. The exacting partially dentate or edentulous patient in the future will spend more time consulting the practice and dental laboratory. Here, it is important to be able to supply a suitable concept for every need. In the end result, there is no better feeling for the dental team than to be able to provide patients with a functioning restoration that improves their quality of life.

REFERENCES

- Balshi T. J., Wolfinger G. J., Alfano S. G. & Balshi S. F. (2016) The Retread: A Definition and Retrospective Analysis of 205 Implant-Supported Fixed Prostheses. *International Journal of Prosthodontics* **29**: 126–31.
- Budtz-Jorgensen E. & Bochet G. (1995) Conception de la prothèse partielle adjointe/Zur Gestaltung von Teilprothesen. *Schweizer Monatsschrift für Zahnmedizin = Revue mensuelle suisse d'odontostomatologie = Rivista mensile svizzera di odontologia e stomatologia/SSO* **105**: 507–514.
- Bürger M. (1960) Altern und Krankheit als Problem der Biomorphose, Leipzig: VEB Thieme.
- Chen J. & Engelen L. (2012) Food Oral Processing: Fundamentals of Eating and Sensory Perception, Chichester, West Sussex: Blackwell Publishing Ltd.
- Jordan A. R. & Micheels W. (2016) Fünfte Deutsche Mundgesundheitsstudie (DMS V). Fifth German Oral Health Survey, Köln: Deutscher Zahnärzte Verlag DÄV GmbH.
- Katsoulis J., Brunner A. & Mericske-Stern R. (2011) Maintenance of implant-supported maxillary prostheses: a 2-year controlled clinical trial. *International Journal of Oral & Maxillofacial Implants* **26**: 648–656.
- Kern J. S., Kern T., Wolfart S. & Heussen N. (2016) A systematic review and meta-analysis of removable and fixed implant-supported prostheses in edentulous jaws: post-loading implant loss. *Clinical Oral Implants Research* **27**: 174–195.
- Kern J. S., Wolfart S., Hilgers R. D., Marre B., Scheller H., Strub J., Boning K., Hannak W., Luthardt R. G., Heydecke G., Huppertz J., Pospiech P., Wostmann B., Stark H., Mundt T., Jahn F., Kern M., Edelhoff D. & Walter M. H. (2017) The randomized shortened dental arch study: influence of two different treatments on interdental spacing over 5 years. *Clinical Oral Investigations* **21**: 1945–1951.
- Kobayashi M., Srinivasan M., Ammann P., Perriard J., Ohkubo C., Müller F., Belser U. C. & Schimmel M. (2014) Effects of in vitro cyclic dislodging on retentive force and removal torque of three overdenture attachment systems. *Clinical Oral Implants Research* **25**: 426–434.
- McKenna G., Allen F., Schimmel M. & Müller F. (2015) Editorial: Who's picking up the bill? *Gerodontology* **32**: 161–162.
- Mercouriadis-Howald A., Rollier N., Tada S., McKenna G., Igarashi K. & Schimmel M. (2018) Loss of natural abutment teeth with cast copings retaining overdentures: a systematic review and meta-analysis. *Journal of Prosthodontic Research in press*; JPOR-D-17-00377R3.
- Müller F., Duvernay E., Loup A., Vazquez L., Herrmann F. R. & Schimmel M. (2013) Implant-supported mandibular overdentures in very old adults: a randomized controlled trial. *Journal of Dental Research* **92** (12 Suppl): 154S–60S.
- Müller F. & Schimmel M. (2016b) Revised Success Criteria: A Vision to Meet Frailty and Dependency in Implant Patients. *International Journal of Oral & Maxillofacial Implants* **31**: 15.
- Phillips K. & Wong K. M. (2001) Space requirements for implant-retained bar-and-clip overdentures. *Compendium of Continuing Education in Dentistry* **22**: 516–518, 520, 522.
- Rowe J. W. & Kahn R. L. (1997) Successful aging. *The Gerontologist* **37**: 433–440.
- Schimmel M., Cantin Y., Srinivasan M. & Müller F. (2016) Digitale Prothese im klinischen Test. teamwork: *Journal of Continuing Dental Education* **19**: 216–230.
- Schimmel M., Katsoulis J., Genton L. & Müller F. (2015) Masticatory function and nutrition in old age. *Swiss Dental Journal* **125**: 449–454.
- Schimmel M., Müller F., Suter V. & Buser D. (2017a) Implants for elderly patients. *Periodontology 2000* **73**: 228–40.
- Schimmel M. & Zimmermann P. (2017b) A maxillary overdenture retained by four Straumann® Novaloc® abutments. *The Dental Technician* **70**: 10–11.
- Schley J.-S., Terheyden H., Wolfart S., Boehme P., Gómez-Róman G., Keese E., Kern M., Pilgrim C., Reinhardt S., Weber A. & Schütte U. (2013) AWMF 083/010 – S3-Leitlinie: Implantatprothetische Versorgung des zahnlosen Oberkiefers. <http://www.awmf.org/leitlinien/detail/II/083-010.html> 2013;10.11.2015.
- Schneider C., Zemp E. & Zitzmann N. U. (2017) Oral health improvements in Switzerland over 20 years. *European Journal of Oral Sciences* **125**: 55–62.
- Silla M., Eichberger M. & Stawarczyk B. (2016) Polyetherketonketon (PEKK) als Restaurationswerkstoff in der modernen Zahnmedizin: eine Literaturübersicht. *Quintessenz Zahntechnik* **42**: 176–190.
- Slade G. D., Akinkugbe A. A. & Sanders A. E. (2014) Projections of U.S. Edentulism prevalence following 5 decades of decline. *Journal of Dental Research* **93**: 959–965.
- Stenman U., Ahlqvist M., Bjorkelund C. & Hakeberg M. (2012) Oral health-related quality of life – associations with oral health and conditions in Swedish 70-year-old individuals. *Gerodontology* **29**: 440–446.
- Tada S., Ikebe K., Matsuda K. & Maeda Y. (2013) Multifactorial risk assessment for survival of abutments of removable partial dentures based on practice-based longitudinal study. *Journal of Dentistry* **41**: 1175–1180.
- Zembic A., Tahmaseb A., Jung R. E. & Wismeijer D. (2017) One-year results of maxillary overdentures supported by 2 titanium-zirconium implants – implant survival rates and radiographic outcomes. *Clinical Oral Implants Research* **28**: 60–67.
- Zimmermann P. & Schimmel M. (2016) Exzellente Dentale Ästhetik. *Quintessenz Zahntechnik* **42**: 1161–1162.