

Chapter 7

Management of the edentulous patient

Mericske-Stern RD, Taylor TD, Belser U. Management of the edentulous patient.

Clin Oral Impl Res 2000: 11 (Suppl.): 108–125. © Munksgaard 2000.

Being edentulous is a handicap, and the main objective of implant placement is to provide support of fixed prostheses or to stabilize complete dentures in the edentulous jaw. Clinical experience and clinical studies have demonstrated the broad application of non-submerged ITI implants in prosthetic therapy in standard sites and in situations of advanced atrophy or substantial loss of tissue. The ITI implant was developed for universal use in partially and completely edentulous patients and for replacement of single missing teeth. The abutment system offers the choice of both removable and fixed prostheses with identical secondary parts. The present article describes the use of ITI implants for prosthodontic rehabilitation in the completely edentulous jaw. Indications and various types of fixed or removable prostheses, alternatives and variations of design are discussed. Prosthetic design is dependent on the number and location of implants, and conversely, the number of implants that can be placed will determine the choice of prosthesis. Treatment planning in general and with respect to individual anatomic-morphologic conditions is described for the upper and lower jaw. Details of clinical procedures with ITI implants related to the specific design of prostheses are presented. Biomechanical aspects of fixation and stabilization of prostheses and aspects of occlusion to be built up complete the overview.

**Regina D. Mericske-Stern¹,
Thomas D. Taylor², Urs Belser³**

¹Department of Prosthodontics,
University of Bern, Bern, Switzerland;

²Department of Prosthodontics,
University of Farmington, CT, USA;

³Department of Prosthodontics,
University of Geneva, Geneva,
Switzerland

Key words: ITI implants – edentulous
jaw – treatment planning – number of
implants – overdentures – fixed
prosthesis – occlusion

PD Dr. R. Mericske-Stern, University
of Bern, Freiburgstrasse 7,
3010 Bern, Switzerland
Tel.: +41 31 632 25 39
Fax: +41 31 632 49 33
e-mail: regina.mericske@zmk.unibe.ch

For many patients, being edentulous must be regarded as a handicap with respect to oral function and psychosocial impact on quality of life. As a result, restoration of oral function through oral surgery and placement of implants is often welcome.

Long-term studies have demonstrated that the edentulous jaw can be restored successfully with implant-supported fixed prostheses (Zarb & Schmitt 1989, 1990a, 1990b; Adell et al. 1990; Quirynen et al. 1992). The success rate has been defined at various times by various authors (e.g. Albrektsson et al. 1986; Smith & Zarb 1989; Buser et al. 1991; Albrektsson & Zarb 1993; Roos et al. 1997), and different limits have been set for the upper and lower jaw: $\geq 95\%$ and $\geq 90\%$ after 5 and 10 years for the mandible and $\geq 90\%$ and $\geq 85\%$ for the maxilla, respectively.

This definition of success has been first applied to fixed implant prostheses in the edentulous jaw. Nowadays it appears that mandibular implants supporting overdentures are particularly successful

(Batenburg et al. 1998), whereas for maxillary implants an increased failure rate is reported. This increased failure rate has mainly been observed with Brånemark fixtures; for ITI implants the results of only a small number of patients are available. Recently, multicenter studies of ITI implants have reported on a small number of edentulous maxillary jaws that were restored and maintained successfully during a still-restricted observation period (Buser et al. 1997, 1999).

Nowadays the use of implants has a great impact on the prosthodontic treatment of the edentulous patient. A variety of prosthetic designs associated with implant prostheses can be observed, and some new designs have emerged in response to the specific clinical conditions of the edentulous jaw provided with implants. Valid clinical methods and treatment strategies – involving the implant technology – exist to ensure the quality of prosthetic reconstruction. Hence, with regard to some special implant indications, specific prosthodontic principles are needed.

In many cases the treatment of the edentulous maxilla will require more elective procedures than are necessary for the mandible, particularly with respect to the following criteria:

- degree of atrophy of the residual jaw;
- prospective location of the implants and inclination of the implant axis;
- tissue volume dimensions;
- facial morphology;
- esthetics;
- function and phonetics.

In general, the following criteria will determine the treatment planning of the edentulous jaw:

- the prosthetic design will depend on the distribution of the implants over the arch, their location and their number;
- the natural dentition or type of prosthesis in the opposing jaw will influence the implant-prosthetic design;
- the intermaxillary relationship has to be considered;
- the occlusal scheme is influenced by all these factors;
- esthetic considerations have to be involved.

In the context of these criteria, implant prostheses must be planned, designed and managed for the edentulous jaw.

Indications for implants in completely edentulous jaws

The main objective of implants in the edentulous jaw is either 1) to avoid removable complete dentures by placement of implant-supported fixed prostheses or 2) to stabilize complete dentures by placement of implant-retained overdentures.

Local anatomic/morphologic conditions and general patient-related factors determine the choice of prosthesis. In general, more implants are required for support of fixed prostheses than for overdenture retention. Therefore, in many cases the indication for fixed prostheses will be limited due to inadequate structure of the bone, unless additional surgical procedures such as bone augmentation by graft procedures are used. This is particularly true for the maxilla, and implies a more specific patient selection than is necessary for simple implant-prosthetic procedures of the mandible. Here, as well as in the case of advanced atrophy, a standard surgical and prosthetic protocol can often be utilized.

Indications for overdentures

The indications may be different for the upper and lower jaw.

Mandibular overdentures

Mandibular overdentures supported by only a few intraforaminal implants are regarded today as a geriatric treatment modality. The indication comprises a large segment of older patients who will profit from implant-retained complete dentures if they lose their teeth in advanced age. In addition, mandibular overdentures may benefit older patients who, having had complete dentures for many years, lose their motor skills and no longer feel able to wear complete dentures.

This problem is observed much more often for the edentulous mandible than maxilla. Even with advanced atrophy, standard surgical implant procedures can be applied for mandibular overdentures. Reduced treatment goals – e.g. the placement of only two implants – will minimize the risk to patients and tissues.

The recent literature (for review see Batenburg et al. 1998) exhibits a high success rate for mandibular overdentures, with the use of different implant systems and a varying number of implants (Batenburg et al. 1994; Wismeyer et al. 1995; Spiekermann et al. 1995). The success of using fewer (generally two) implants has been clearly demonstrated (Mericske-Stern et al. 1994; Mericske-Stern & Zarb 1993; Mericske-Stern 1990; Mombelli & Mericske-Stern 1990), but has not entirely become the standard clinical protocol in daily practice. Age itself is no longer regarded as a contraindication (Bryant & Zarb 1998), and studies with ITI implants have demonstrated that mandibular overdentures are highly successful in older patient groups (Mericske-Stern & Zarb 1993; Cune et al. 1994; Zarb & Schmitt 1994, 1995). Thus, mandibular overdentures are a true alternative to fixed prostheses in terms of economics and time-saving procedures.

Maxillary overdentures

While most patients asking for mandibular overdentures are completely edentulous in both jaws, the maxillary overdenture is indicated for patients who have natural teeth in the opposing mandible or fixed or removable prostheses supported by implants and teeth.

Studies published in the last 5 years exhibit a surprisingly high failure rate for maxillary overdentures, i.e. over 20% (Jemt 1991; Jemt 1993; Jemt et al. 1996; Hutton et al. 1995). This failure rate is significantly increased in comparison with fixed prostheses or mandibular implants. A critical analysis of the treatment outcomes revealed that the indication for overdentures was often given in an emergency situation (Palmqvist et al. 1994), meaning that overdentures were a substitute for failing fixed prostheses and were prescribed if ade-

quate placement of implants to support fixed prostheses was not possible (Jemt 1991). Otherwise, in properly planned overdentures, an increased survival of implants was found (Bergendal & Enquist 1998; Widmark et al. 1998). The marginal bone surrounding the implants was maintained at the same level as with fixed prostheses (Palmqvist et al. 1994, 1996), also in ridges with advanced atrophy.

One advantage of overdentures is that their utilization may be more consistent, with optimum placement of the implants with regard to the remaining bone structures. Full congruence of tooth position on the prosthesis and implant location is not necessary for overdentures. Fewer implants are needed than with fixed prostheses. Furthermore, requirements of extraoral esthetics such as facial support can be fulfilled and problems with phonetics and oral hygiene are often better resolved with overdentures. In fact, hygiene procedures are mostly facilitated with removable prostheses; however, under maxillary overdentures soft tissue hyperplasia may develop.

Indications for fixed prostheses

For the mandible, in many situations a fixed prosthesis or an overdenture can be suggested, according to the individual needs of the patient. Even in the case of advanced atrophy a screw-retained cantilever prosthesis may be mounted on 4 to 6 intraforaminal implants. For this type of reconstruction a full congruence of implant and tooth position is not required. If bone structure and bone quality are adequate, a fixed prosthesis with a crown-and-bridge design can be fabricated, supported by intraforaminal and posterior implants. Esthetic or speech problems are rarely encountered with any type of mandibular reconstruction.

While for the edentulous mandible both options – i.e. fixed and removable prostheses – can usually be offered, the anatomic-morphologic problems of the maxilla and esthetic requirements must be underscored and will determine the choice of the prosthetic design. A younger segment among patients with edentulous maxilla will ask for fixed bridgework. Patients asking for fixed implant-prostheses in the edentulous upper jaw often present with a full complement of natural teeth or fixed reconstruction in the opposing jaw. The inability to adapt to removable prostheses is based on psychosocial aspects and/or on adverse morphological conditions of the oral cavity which would hinder wearing complete dentures. A screw-retained cantilever prosthesis is not frequently recommended for the maxilla, due to esthetic problems and impaired hygienic procedures. In most cases a combination of several

of the following aspects will determine the respective treatment plan:

- anatomic and morphologic structure of the maxilla;
- bone quantity;
- esthetic considerations: facial support, tooth length, soft tissue management;
- ease of repair;
- economics.

Favorable conditions related to bone quantity and quality for elective placement of multiple implants are required for fixed bridgework. Clinical experience today shows that the soft tissue may be managed successfully in case of one single-tooth replacement (Belser et al. 1998; Salama et al. 1995). Recreating a well-contoured soft tissue border around implants over an entire dental arch has not yet been documented to be practicable. With fixed prostheses, in contrast to overdentures, phonetic problems have been reported (Jemt 1991; Jemt 1994; Lundqvist et al. 1992). In addition, compensation for lost hard and soft tissue becomes difficult (Albora 1997) and is a problem that requires special attention in the planning phase. The intermaxillary distance between the incisal edge of the lower teeth and the contour of the maxillary jaw should not exceed 15 mm, otherwise the teeth will become too long and an overdenture would be a better indication. A low lip-line (no gummy smile) is advantageous for fixed prostheses with regard to esthetic and cosmetic demands for the upper jaw. Complex skeletal, alveolar and occlusal conditions such as skeletal class 3 may determine the choice of a removable prosthesis. With respect to various extraoral and intraoral diagnostic criteria, overdentures may often become the preferred option if the maxillary jaw is restored with implants.

Table 7.1 gives an overview of the intra- and extraoral diagnostic criteria for the choice of fixed or removable implant-supported prostheses in the edentulous maxilla.

Number of implants and choice of prosthesis

The number of implants to be placed depends on the type of prosthesis and the choice of prosthetic design. Conversely, the number of implants that can be placed with respect to anatomic-morphologic conditions will determine to a certain degree the type and design of prosthesis. Additionally, the size, curvature and shape of the ridges determine the distribution of the implants over the arch.

Mandibular overdentures

For the placement of mandibular overdentures in edentulous older patients wearing complete den-

Table 7.1. Summary: diagnostic criteria for the maxilla

Extraoral	Fixed	Removable	Intraoral	Fixed	Removable
Lip-line	Low	High	Ridge (shape)	Vertical	Buccal inclination
Tooth display	Little	Distinct		Convex	Buccal concavity
Facial support, lip support	No need	Necessary	Intermax. dist.	≤10 mm	>15 mm
			Intermax. relation	Neutral	Skeletal III
				Deep overbite	Crossbite
			Mucosa	Thick, keratinized	Thin, mobile

tures, two to four interforaminal implants will serve the purpose and satisfy the patients' demands. There is no scientific evidence that failures occur more often with a small number of implants, namely two for overdenture retention. Single attachments or bars can be mounted. If, due to advanced atrophy, the implant length becomes <8

mm, or if narrow, thin ridges require a reduced implant diameter (3.3 mm), the use of three or four implants is recommended. In the presence of large or V-shaped anterior ridges, three to four implants will provide for a more favorable design of the bar and the prosthesis.

It is not necessary to recommend four intraforaminal implants for mandibular overdentures as a standard procedure. It must be taken into account that bar segments may become rather short, and short female bar retainers are subject to frequent loosening or loss. The length of the bar segments should not be less than 15 mm, and can range from 15 to 25 mm. If four intraforaminal implants are placed they must be well spaced, or as an alternative a cantilever-fixed prosthesis can be mounted.

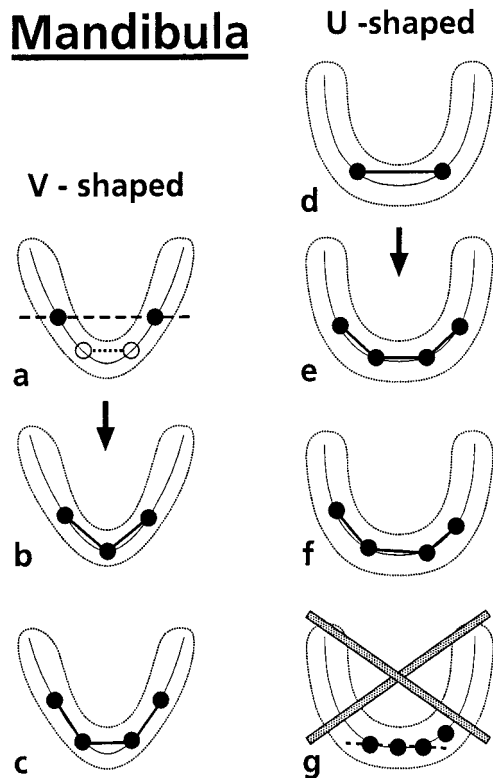


Fig. 7.1. The distribution of intraforaminal implants depends on the shape of the ridge. a) Bar connector would interfere with space for tongue. Ball anchors are suggested; however, this will result in a hinging movement. Implants located in more anterior position: this may result in inadequate length of the bar. b/c) Three or four implants with a connecting bar are in better harmony with the shape of the ridge. Four implants allow for fixed prosthesis. d) Two anterior implants with a connecting bar of adequate length. e) U-shaped mandibular jaw with large curvature will allow for placement of four implants and a connecting bar. f) This configuration is also favorable for mounting of a fixed screw-retained cantilever prosthesis. g) Alignment of the implants in a rather straight line does not favor fixed prostheses.

- 2 implants for mandibular overdentures ⇒ geriatric treatment conception;
- 3 or 4 intraforaminal implants: if reduced diameter or length of 6 mm;
- 3 or 4 intraforaminal implants: length of bar segments must be adequate;
- 4 intraforaminal implants: fixed cantilever-prostheses may be recommended as an alternative.

Fig. 7.1 gives an overview of the distribution of mandibular implants for overdenture connection. A clinical situation with two intraforaminal mandibular implants is shown in Fig. 7.2.

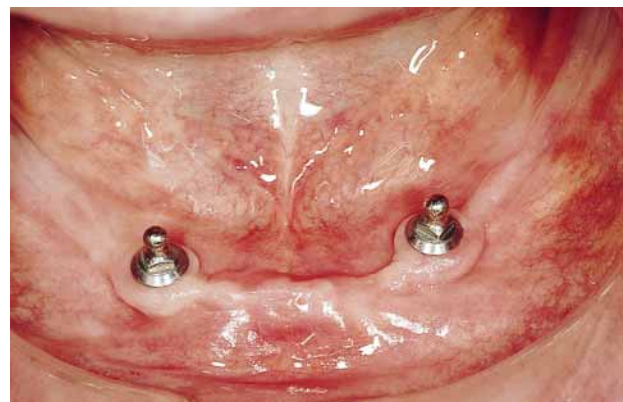

Fig. 7.2. Two mandibular implants with ball anchors.

Maxillary overdentures

The actual state of the art for maxillary overdentures is to adopt the biomechanical and technical concept of fixed prostheses—namely, multiple implants and a rigid connection of the prostheses to the implants. In the maxilla most often bone quality and quantity are not favorable: i.e. according to the criteria of Albrektsson et al. (1986), degree of atrophy corresponds to class C and D. Four to six well-spaced implants, evenly distributed over the arch and connected by a bar, will enhance the stability of the overdenture. The implants are mostly located in the anterior part of the upper jaw, between the first premolars. Thus, additional surgery such as sinus floor elevation can be avoided in many cases. The implant length should preferably be ≥ 10 mm, and a standard diameter of 4.1 mm is suggested. The literature provides evi-

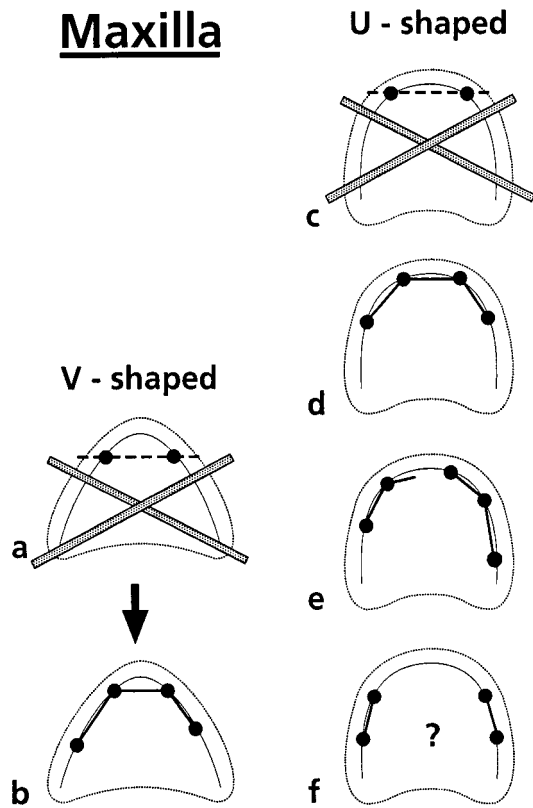


Fig. 7.3. Distribution of maxillary implants for overdenture connection. a) Use of two implants is not the standard procedure. In this situation only ball anchors are suggested; a bar would interfere with the space of the tongue. b) Four implants, well distributed, with a sufficient length of bar segments. c) A bar cannot be recommended. It would result in a hinging movement. d) Four implants, often located in an anterior position due to the extension of the sinus. e) Depending on the specific anatomic situation, the bar may be divided into segments. An irregular number of implants can also be used. f) In rare cases, more bone is available in the posterior part of the maxilla. Parallel placement of two separate bars might be recommended.

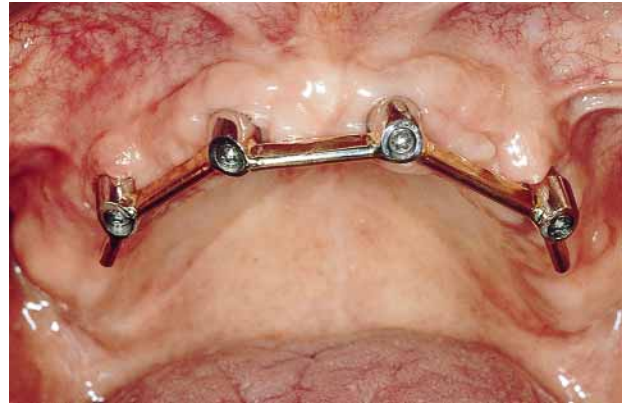


Fig. 7.4. Clinical situation with four well-spaced implants in the anterior part of the maxilla and a bar connector.

dence of an increased failure rate for short implants. Therefore, the use of implants which are “non-standard” in length or diameter must be compensated for by a sufficient number of standard-sized implants. A connecting bar cannot be mounted to two implants in the maxilla, due to the anatomic-morphologic conditions. Thus, the use of two maxillary implants for overdenture support is rarely recommended. The use of two ball anchors results in a hinging movement of the denture that may cause discomfort.

- the minimum number of implants is preferably not less than four;
- using two implants is not a standard procedure;
- the implants should be evenly distributed over the arch;
- implants of 6 mm length should be avoided;
- implants with a reduced diameter (3.3 mm) have to be combined with implants of standard diameter.

Fig. 7.3 gives an overview of the distribution of maxillary implants for overdenture connection. A clinical situation with maxillary implants for overdenture connection is shown in Fig. 7.4.

Fixed prostheses in the mandible and maxilla

A typical feature of the mandibular fixed cantilever prosthesis is 4 to 6 interforaminal implants. Congruence of implant location and tooth position is not necessary. This type of prosthesis is favored by a distinct anterior curvature of the jaw. If the implants are aligned on a straight anterior line this will result in a biomechanically unfavorable situation for loading and designing of the prostheses. The material and characteristics resemble removable partial dentures. The prosthesis often has shortened dental arches.

For placement of full-arch bridgework the most important prerequisite is the congruence of im-

Table 7.2. Number of implants and type of prosthesis

Location	Implants	Type of prostheses	Remarks	
Lower Jaw • anterior	2	Overdenture	Bar	Design of complete
		Overdenture	Ball anchor	
	3-4	Overdenture	Bar (rigid)	Cave: Cantilevers Cave: Cantilevers 2-3 segments
	4-6	Fixed cantilever prosthesis (screw-retained)		
		Bridgework		
• anterior/posterior	>4	Bridgework		
Upper Jaw	2	Overdenture	Ball anchor	Not standard, complete denture
	4-5	Overdenture	Bar (rigid)	Horseshoe-design
	>4-8	Bridgework		2-3 segments
		Individual abutments		Correction of axis

plant location and tooth position. This is necessary for esthetic and cosmetic reasons, and moreover for a favorable perioprosthesis design that provides good access for hygienic procedures. The preferred number is 6 to 8 implants for both maxilla and mandible. The implants are, whenever possible, evenly distributed over the entire arch, i.e. anterior (intraforaminal) and posterior in the mandible and maxilla, thus avoiding long cantilevers. Further, a segmented bridgework can be fabricated. More-

over, depending on individual oral conditions, shortened dental arches may be considered, if fixed bridgework is placed. Again, if implants with “non-standard” size are selected this should be compensated for by including implants of standard lengths and diameters. The fixation of the bridgework can be performed by screw retention or by cementation. While screw retention is more likely to be feasible in the mandible, with perpendicular implant axes and good access to the screw holes, this may be difficult in the maxilla, where divergent implant axes are observed.

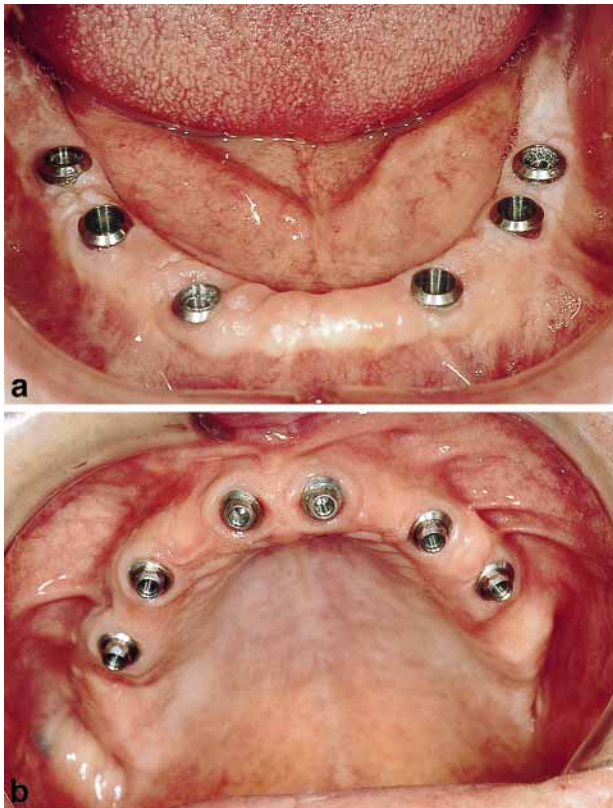


Fig. 7.5. a) Six mandibular implants for support of a fixed (screw-retained) bridgework with full congruence of implant and tooth position. b) Six maxillary implants for mounting of a cemented fixed bridgework with full congruence of tooth and implant position.

- >4 implants are necessary (6 to 8 implants);
- one implant per one missing tooth is not necessary;
- congruence of implant and prospective tooth position is necessary;
- bridgework with a segmented design can be fabricated.

Table 2 summarizes the suggested numbers of implants related to different types of prostheses. Fig. 7.5a shows mandibular implants for fixed prostheses, and Fig. 7.5b shows maxillary implants for fixed prostheses.

Treatment planning

Prosthetic treatment of the edentulous patient or jaw with implants is demanding because it usually implies a complete rehabilitation of oral structures and facial morphology. Treatment planning is the first and most important step in clinical implantology with respect to surgical, prosthetic and laboratory procedures. Optimum placement of the implants in the bone must not interfere with esthetics and a correct design of the prosthesis. Intraoral and extraoral diagnosis is followed by assessment of the old dentures with regard to vertical dimension of occlusion, function and esthetics. Alginate impressions and panoramic radiographs should complete this first step of plan-

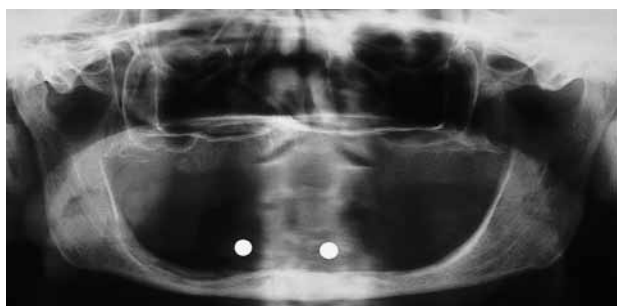

Fig. 7.6. Panoramic radiograph with metallic markers in interforaminal position.

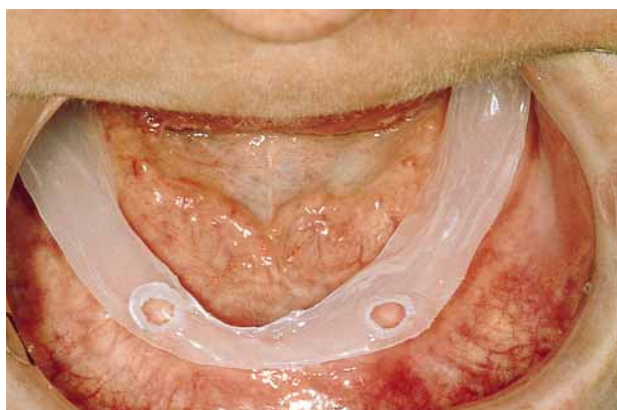


Fig. 7.7. Radiographic template is used as surgical guide.

ning. Metallic markers are helpful landmarks for assessment of the prospective implant location and for diagnosis of anatomic structures of the edentulous jaw. During the non-submerged healing phase, provisional dentures must be carefully adapted for temporary use to protect the implants from inadvertent loading. Clinical studies give evidence of a highly successful non-submerged healing period (Mericske-Stern et al. 1995; Behneke et al. 1997; Buser et al. 1997, 1999). Only well-fitting old dentures may be used. This preliminary clinical and radiographic diagnosis determines whether the envisaged therapeutic measures can be performed. More detailed information about individual oral conditions is necessary if extended implant overdentures of the maxilla and/or fixed bridgework are planned.

Mandibular overdentures

Lateral radiographs are not necessary but may provide useful information about the shape and lingual profile of the mandibular bone. If radiographic templates with markers are fabricated for panoramic radiographs these can be adapted and used as surgical templates. Existing old dentures may be used as surgical templates as well. Fig. 7.6

shows a panoramic radiograph with metallic markers for quantitative analysis of bone. In Fig. 7.7, a template is used as the surgical guide.

Overdentures in the maxilla and fixed prostheses in the maxilla or mandible

These types of reconstruction usually require a more specific treatment plan (Mericske-Stern 1998). The prosthodontic treatment of the maxilla with implants is challenging and determined by inherent problems that have been presented in anecdotal case reports (Hallmann & Carlsson 1996). These are: divergent implant axis, long teeth, wide interdental spaces, missing congruence of implant location and tooth position, and buccal access to the occlusal screw. Such adverse morphological effects can be more easily eliminated with the utilization of overdentures instead of fixed prostheses. Nonetheless, treatment planning, particularly for the maxilla, usually has to consider both treatment options – fixed and removable prostheses – because patients often ask first of all for fixed prostheses. A tooth setup in wax should be performed for planning of fixed prostheses, and will ultimately determine whether the edentulous jaw can be restored with bridgework or overdentures should be used.

Mounted casts and the tooth setup are used to consider aspects of design, and to assess function, occlusion and esthetic aspects of the prospective reconstruction, such as vertical dimension of occlusion, relationship of maxillary to mandibular jaw, occlusion, phonetics, facial support and cosmetics. The orientation index obtained from the tooth setup is utilized to analyze dimensions of tissue volume and to compare the prospective implant and tooth axis. The tooth setup is further used to fabricate templates for radiographs with

Table 7.3. Treatment planning

Documents	Overdenture		Bridgework	
	Lower	Upper	Lower	Upper
Standard				
Intraoral diagnosis	++	++	++	++
Casts	++	++	-	-
OPT (with markers)	++	++	++	++
(Cephalometric rx)	+	-	-	-
Additional in complex situations				
Mounted casts	+	+	++	++
CT-scan	+	+	+	++
Wax-setup	+	+	++	++
Surgical guide	+	++	++	++
Temporary denture	+	++	+	++

- not necessary. + useful. ++ recommended or necessary.

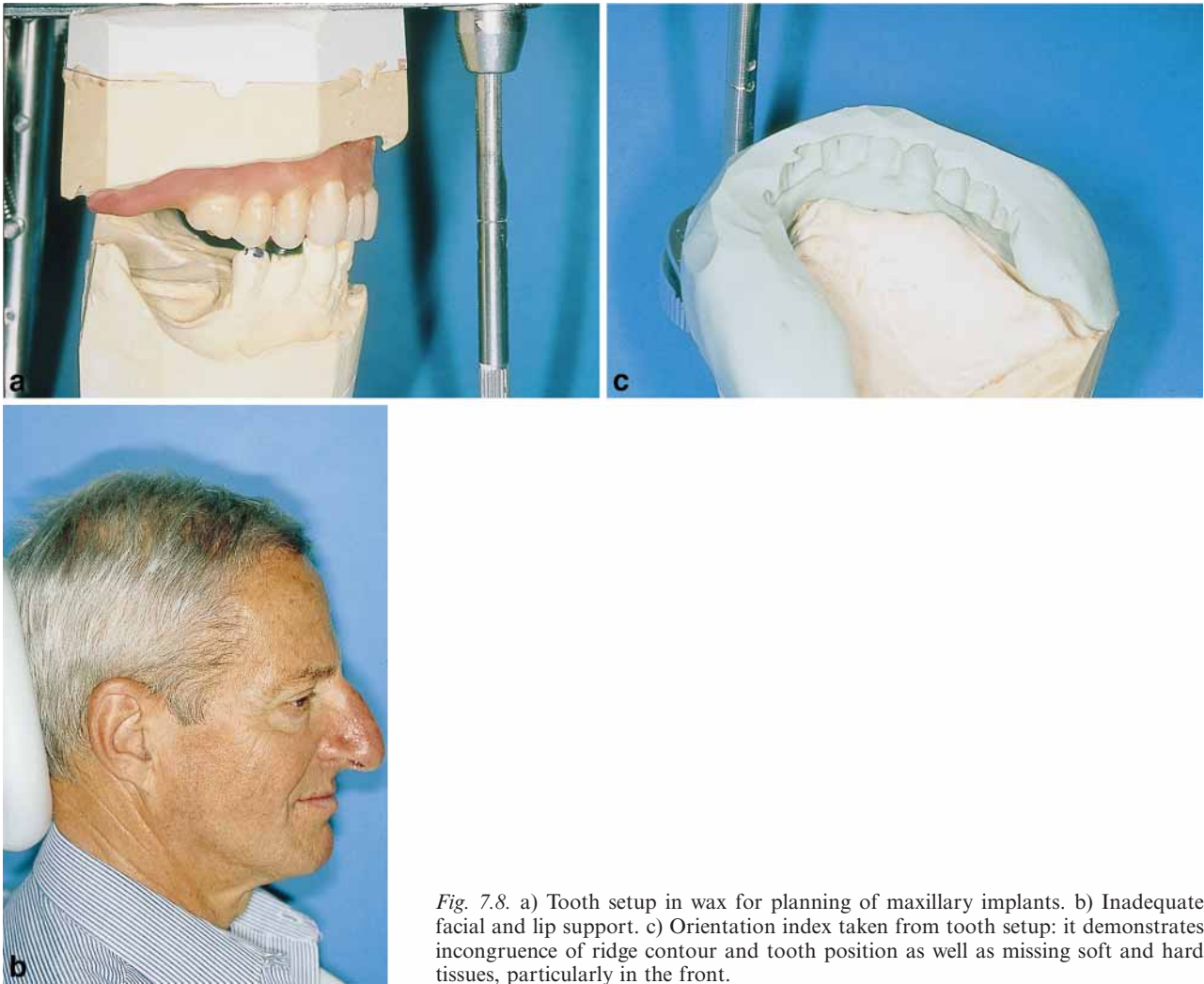


Fig. 7.8. a) Tooth setup in wax for planning of maxillary implants. b) Inadequate facial and lip support. c) Orientation index taken from tooth setup: it demonstrates incongruence of ridge contour and tooth position as well as missing soft and hard tissues, particularly in the front.

markers, to fabricate surgical templates and guides, and to fabricate temporary dentures if necessary. Existing well-fitting and esthetically pleasing dentures can fulfil the same purpose.

For the maxillary reconstruction, a CT-scan combined with a radiographic template and markers that correspond to the prospective tooth position, as determined by the setup, is strongly suggested but is optional for the mandible. Surgical guides are fabricated from radiographic templates or existing dentures. Temporary dentures are adapted from existing dentures or fabricated from the wax setup. Thus the setup is utilized for:

- diagnosis: esthetics, cosmetics
tooth length and tooth position, prospective implant axis
function and phonetics
occlusion, and occlusal plane
vertical dimension of occlusion
denture design;

- fabrication of radiographic templates;
- fabrication of surgical guides;
- fabrication of temporary dentures during the healing phase.

Table 7.3 gives a summary for treatment planning. Figs 7.8a, b and c show casts mounted into the articulator with the corresponding tooth setup and orientation index for assessment of intra- and extraoral esthetics with the patient. In Fig. 7.9a and b, a template and CT-scan are shown. The use of surgical guides fabricated from the tooth setup is demonstrated in Fig. 7.10.

Abutment selection and impression technique

Overdentures and fixed prostheses

Retrievability of all types of prostheses is often recommended for the completely edentulous jaw. Thus, screw retention or cementation with provisional materials is the preferred procedure. Retri-

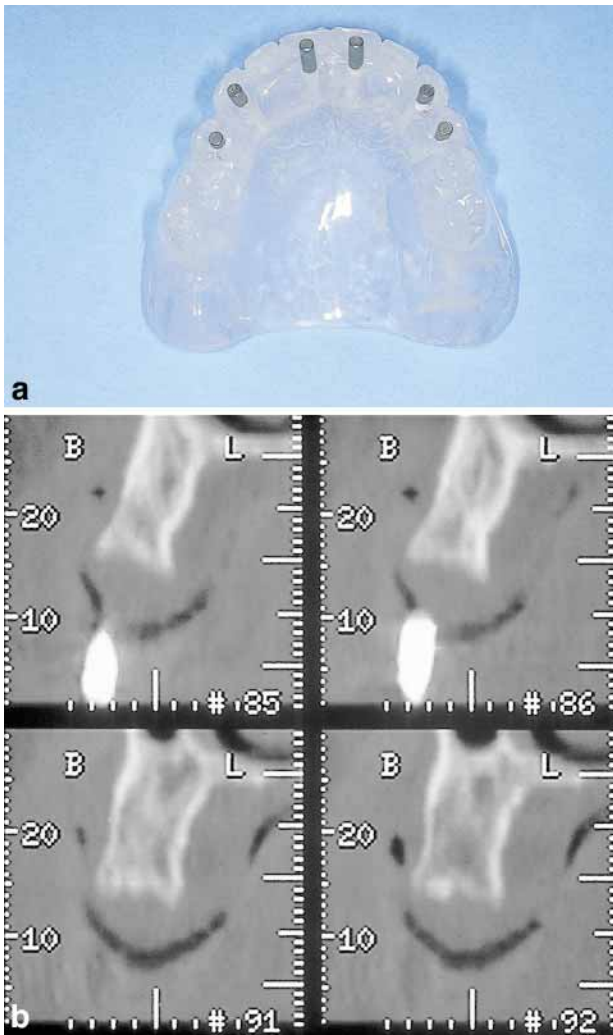


Fig. 7.9. a) Radiographic template: duplication of tooth setup or of a well-fitting existing denture, with titanium pins, indicating tooth position and tooth length. b) CT-scan: pins allow for detailed analysis and measurements.

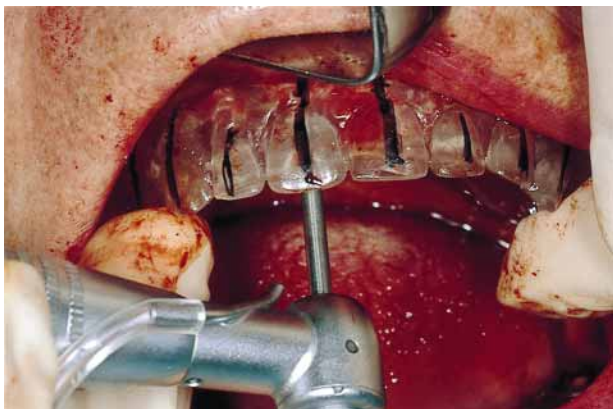


Fig. 7.10. Radiographic template is modified and used as surgical guide for placement of six maxillary implants.

evability is advantageous in case of any complication. In the presence of multiple implants, the removal of one implant will not necessarily lead to changes in the prosthetic superstructures. All retention devices used for removable prostheses with the ITI system, such as bars or retentive anchors of overdentures, are retrievable.

The octa abutment and the corresponding set of prefabricated, secondary parts for clinical and laboratory procedures can be used in all indications, i.e. overdentures and fixed prostheses. This abutment ensures optimum precision in clinical and laboratory procedures, be it in conjunction with the standard implant type or the new Synocta® system. The octa abutment's design, in combination with prefabricated gold copings for the bar, is likely to facilitate good oral hygiene and to avoid plaque accumulation. Full-arch fixed prostheses may be screw-retained. However, the octa abutment also allows for fabrication of individual cast abutments with optimum parallel alignment and correction of non-parallel implant axes. As a consequence, such individual abutments require the cementation of the reconstruction.

Use of the double impression technique is ad-

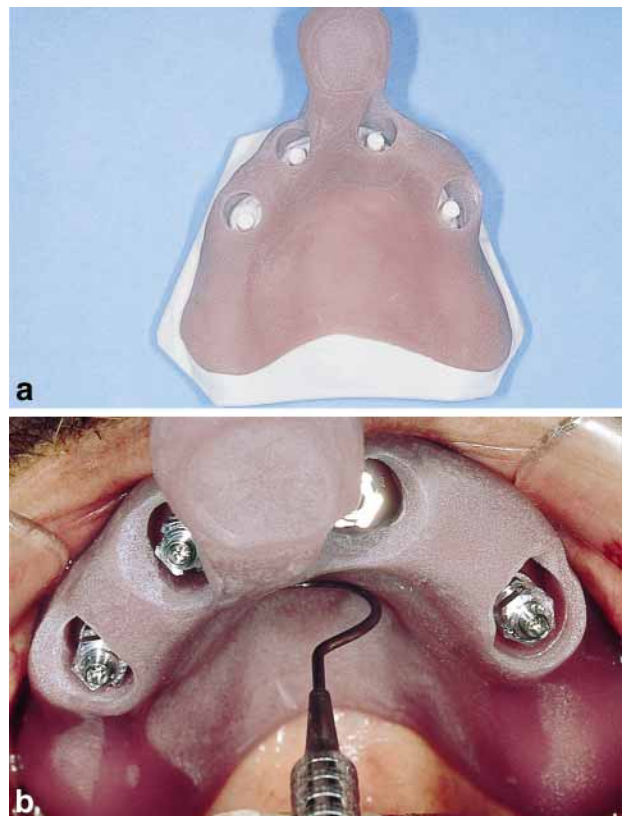


Fig. 7.11. a) Cast with axis indicator of four implants. Individual cast tray with corresponding access holes. A bar is planned. (Same case as Fig. 4). b) Individual tray *in situ*. Transfer copings of octa system are visible.

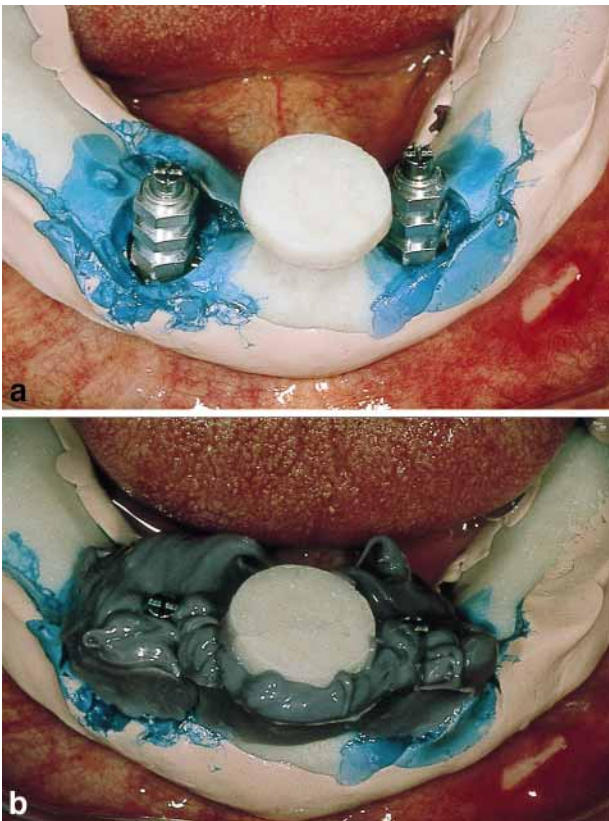


Fig. 7.12. a) Impression with Zn-eugeno paste is taken. Tray is repositioned in mouth with transfer copings *in situ*. b) Fixation of transfer copings with Impregum impression material.

vised for overdentures retained by only two implants. This type of overdenture has characteristics resembling those of a complete denture, with a combination of tissue support and implant retention. For all other indications a one-step technique is indicated. Taking an impression with ball anchors achieves better precision without the use of transfer copings. Individually cast trays are often recommended in the completely edentulous jaw. For optimum design of the individually cast tray, the alginate impression is taken with some direction indicator mounted onto the implants. This is to ensure proper size of the tray above the mounted transfer copings. Ease of access to the occlusal screw through the holes of the individual tray is provided if a screw-retained abutment system is utilized.

- Octa abutment fulfills all indications of the edentulous jaw: bars, screw retention of fixed prostheses, and individually cast abutments for fixed prostheses;
- Retentive anchors: mandibular overdentures, geriatric conception;
- Double impression technique: overdentures supported by two implants;

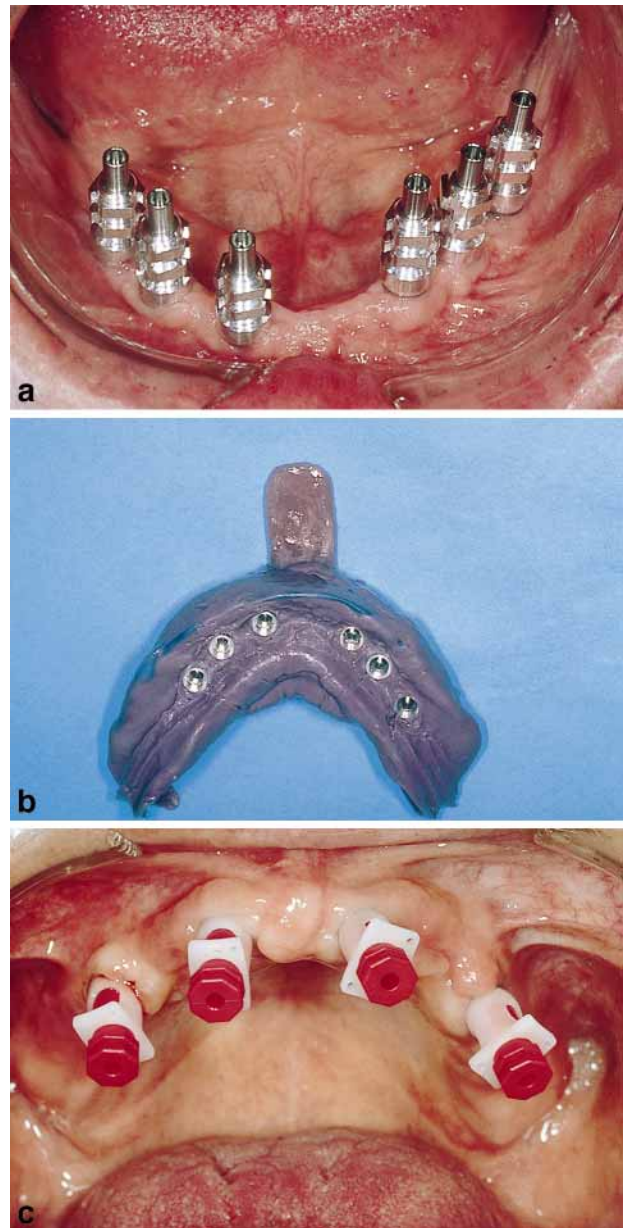


Fig. 7.13. a) Screw-retained transfer copings mounted to mandibular implants. b) Impression is removed, with transfer copings *in situ*. c) Simple transfer system in combination with Synocta® system: click-fit copings *in situ*.

- One-step impression technique: all other indications;
- Individually cast tray with space for the transfer copings is recommended;
- Access to the occlusal screws of the transfer copings is mandatory if screw-retained transfer copings are used.

Figs 7.11a and b demonstrate optimum fabrication of the individual tray for impression with the screw-retained transfer copings. Figs 7.12a and b demonstrate the step-by-step procedure for a

double impression technique with two mandibular implants. Figs 7.13a, b, c show the impression technique with the standard octa abutment and with the Synocta® system.

Retention devices and design of prostheses

Overdentures

If mandibular overdentures are connected to two implants, either a u-shaped bar (rigid retention mechanism), an egg-shaped Dolder bar (stress-breaking retention mechanism=hinging movement) or ball anchors (stress-breaking retention mechanism) may be selected. Short distal cantilevers (5–7 mm) may be added to rigid bars, but their total lengths must be shorter than the central bar segment and are not thought to compensate for inadequate length of the central bar segments.

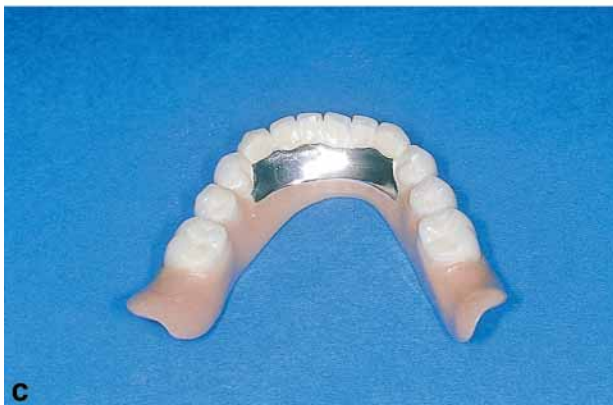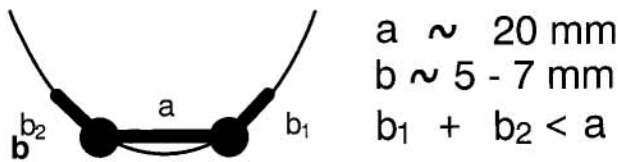
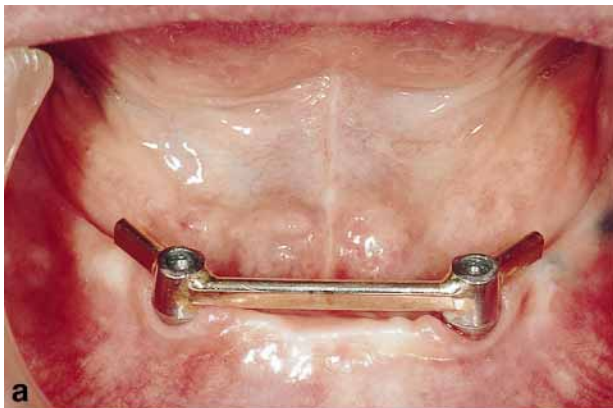


Fig. 7.14. a) Rigid bar connecting two implants, with short distal extensions. b) Schematic explanation for design of extension bars. c) Mandibular overdenture resembles complete denture. Base is reinforced with cast metal framework.

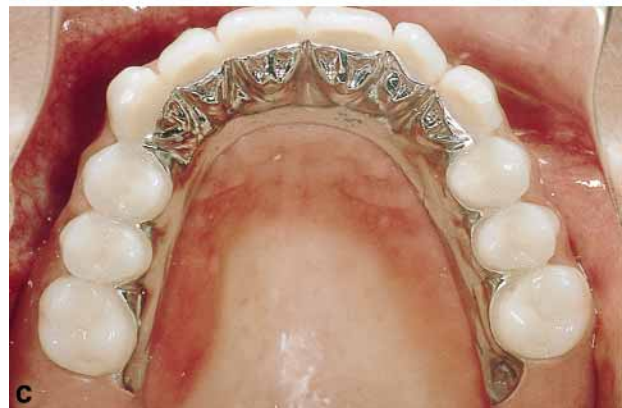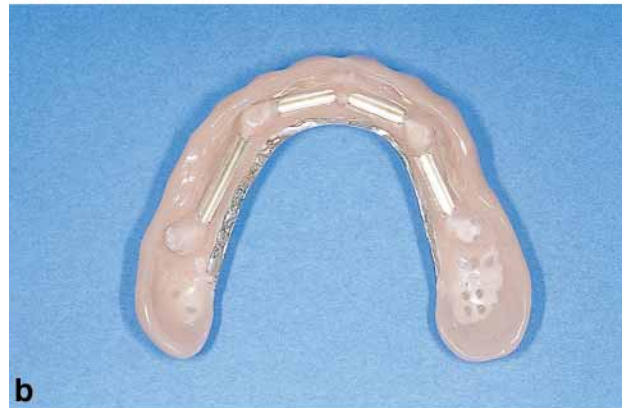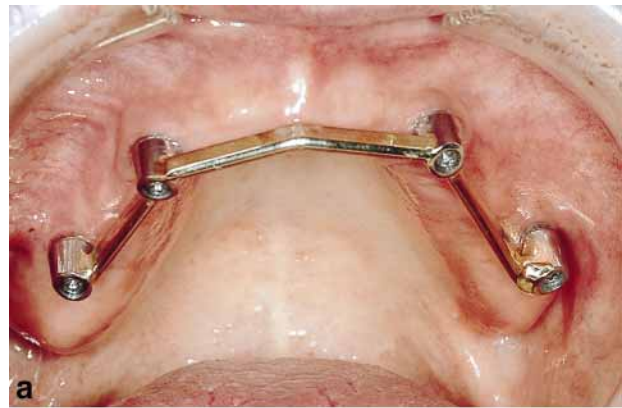


Fig. 7.15. a) Four well-spaced implants and long bar segments. b) Inner surface: female retainers of bar are mounted in the resin denture base. c) Overdenture with a horseshoe design and cast metal framework.

They must not be extended beyond the distal part of the first premolar. A cast metal framework to obtain sufficient stiffness and a thin lingual denture flange may reinforce the denture base. For geriatric patients, particularly those with retentive anchors, this may not be necessary.

With multiple implants, the maxillary overdenture becomes mostly implant-supported regardless of the retention device and bar design. Therefore, for multiple implants, rigid bars are always recommended and a cast metal framework must re-

inforce the denture base to ensure stability and stiffness (Mericske-Stern 1998a). Four to six implants connected by a rigid bar provide high stability and a maximum of support. The overdenture itself has a horseshoe design. This is well tolerated by patients, also from a psychological point of view, because the feeling of wearing complete dentures is absent. An individually cast metal framework is mandatory for a horseshoe design of the maxillary overdenture and provides for adequate stiffness and rigidity of the overdenture. The palatal seal is cast in metal. Female bar retainers are not soldered to the cast metal framework, but rather are mounted in the acrylic denture base. This facilitates prosthetic services like tightening or renewal of retainers. The use of ball anchors with maxillary overdentures is not standard and has the character of a long-term provisional restoration. Full coverage of the palate may become necessary. The connection of overdentures to ball anchors is more favorable if parallel alignment of the implant axes is achieved. With pronounced divergence of the axes, stable fit is not achieved through the female parts.

Based on biomechanical studies with mandibular implants, it has been concluded that rigid bars provide the best distribution of forces in a vertical direction onto the implants (Mericske-Stern et al. 1996a, 1996b; Mericske-Stern 1998b). It seems that short distal cantilevers do not negatively influence the force pattern (Mericske-Stern 1997). With three implants, force magnitudes measured on the central implant are lower in a vertical direction than in a transverse direction (Bürgin et al. 1998). *In vivo* force measurements with maxillary implants connected by a rigid bar or supporting full-arch bridgework have been shown to result in mostly identical force patterns and force magnitudes for both types of prosthesis (Mericske-Stern et al. 1998). From this study the authors concluded that the splinting effect of bars connecting multiple implants might resemble fixed prostheses.

Figs 7.14a–c show mandibular overdentures and explain the design of extension bars connecting mandibular implants. Figs 7.15 a–c show maxillary implants for overdenture connection and details of technical aspects.

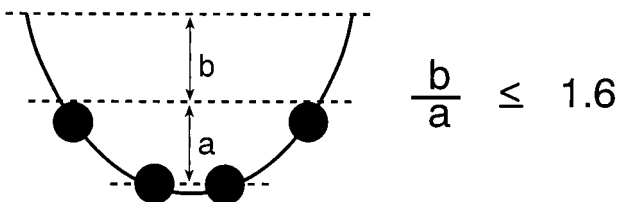


Fig. 7.16. Planning of screw-retained cantilever prosthesis: design and biomechanical considerations.

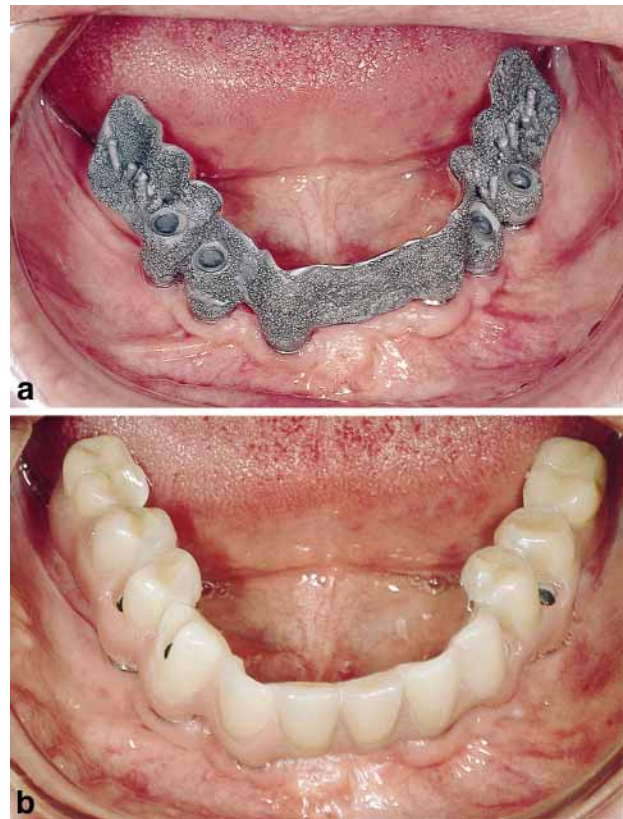


Fig. 7.17. a) Extreme skeletal class 3: cast metal framework of screw-retained cantilever prosthesis *in situ* (same case as Fig. 13a, b). b) Full congruence of tooth and implant position is not necessary. Access to three occlusal screws is buccally located.

Screw-retained cantilever prostheses

A screw-retained fixed cantilever prosthesis is a favorable alternative to overdentures in the mandible, especially for a younger segment of the older population. It is less expensive than a ceramic bridgework. High precision of fit is achieved by fixation of the titanium copings into the framework. The cast framework can either be a gold alloy or a non-precious alloy. The design is consistent with perioprosthetic requirements and the esthetic appearance is not impaired. However, greater manual skills are necessary for daily hygiene procedures than with removable overdentures. The design cannot be recommended for the maxilla for esthetical and functional reasons. Speech problems may arise and a buccal flange becomes necessary to hide the metal structures of the denture or the implant shoulder. The selection of this prosthetic design is based on the morphologic condition of the mandible and the distribution of the implants over the arch.

Fig. 7.16 is a schematic picture explaining the designing of cantilever prostheses. Figs 17.7a and b show a screw-retained cantilever prosthesis.

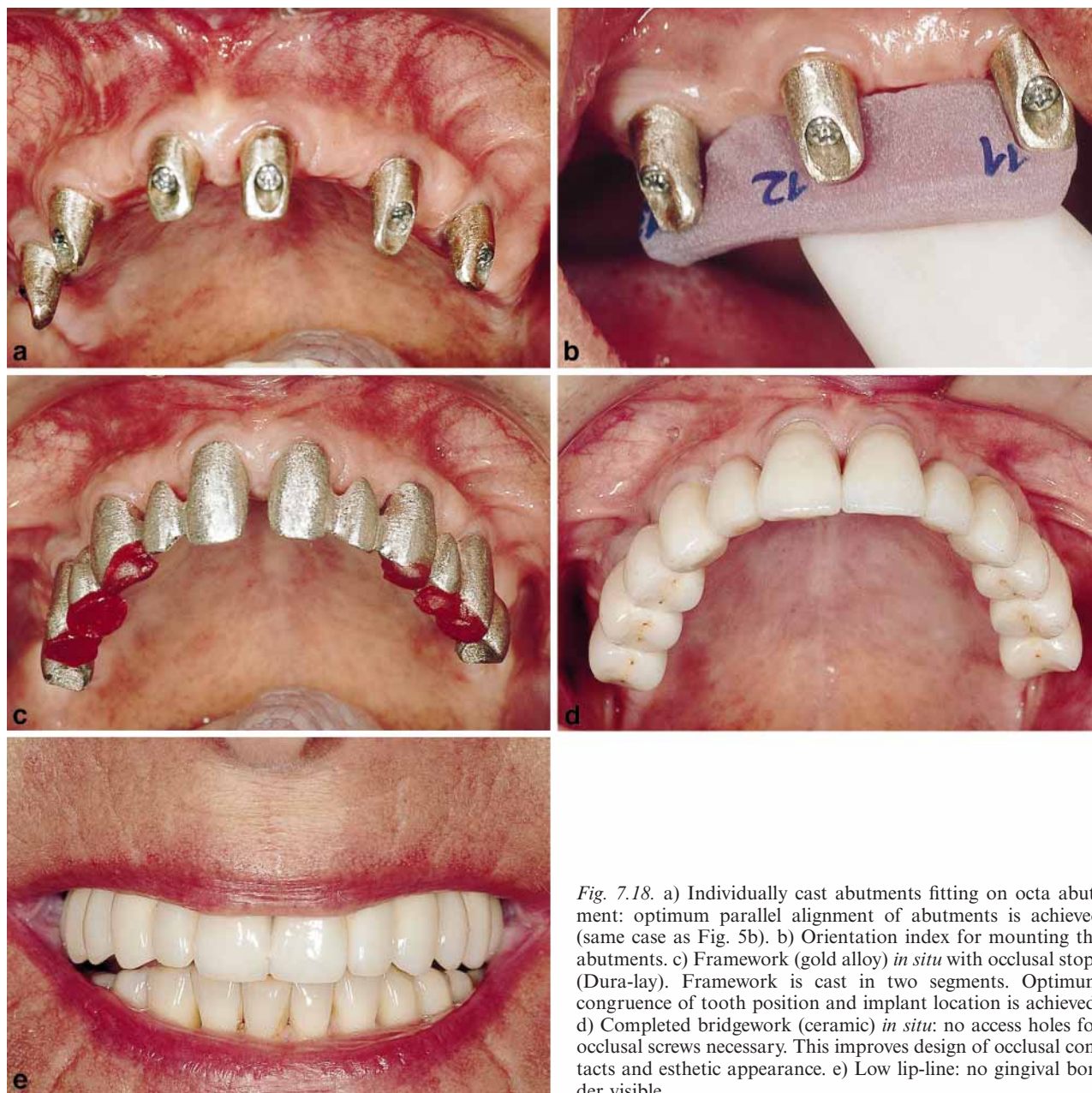

Fig. 7.18. a) Individually cast abutments fitting on octa abutment: optimum parallel alignment of abutments is achieved (same case as Fig. 5b). b) Orientation index for mounting the abutments. c) Framework (gold alloy) *in situ* with occlusal stops (Dura-lay). Framework is cast in two segments. Optimum congruence of tooth position and implant location is achieved. d) Completed bridgework (ceramic) *in situ*: no access holes for occlusal screws necessary. This improves design of occlusal contacts and esthetic appearance. e) Low lip-line: no gingival border visible.

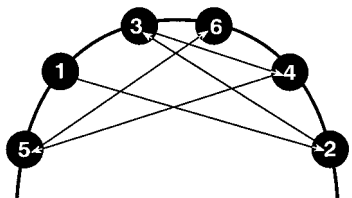
Fixed bridgework: screw-retained or cemented

A fixed bridgework in the maxilla, whether with screw retention or cemented to individual cast abutments, requires congruence of implant location and tooth position. The framework usually is cast from a gold alloy, either with ceramic or acrylic veneers. If the implants are evenly distributed over the entire jaw, a full-arch bridgework can be segmented (i.e. two pieces). This will enhance precision of passive fit of the framework and avoid a splinting effect that might cause discomfort due to its high rigidity. The bridgework favors the criteria

of a perioprosthetic design. While hyperplasia—particularly in the maxilla—of the soft tissues is more often observed with an overdenture, the change to a fixed bridgework will lead to shrinkage of the soft tissue (Jemt et al. 1994). The use of individual cast abutments requires cementation. With regard to the occlusal surface of the teeth this may even be advantageous, since no access for the occlusal screw has to be built up. This may also improve the esthetic appearance of the prosthesis. One disadvantage is that in some cases it may not be possible to remove the prosthesis even though provisional cement has been used.

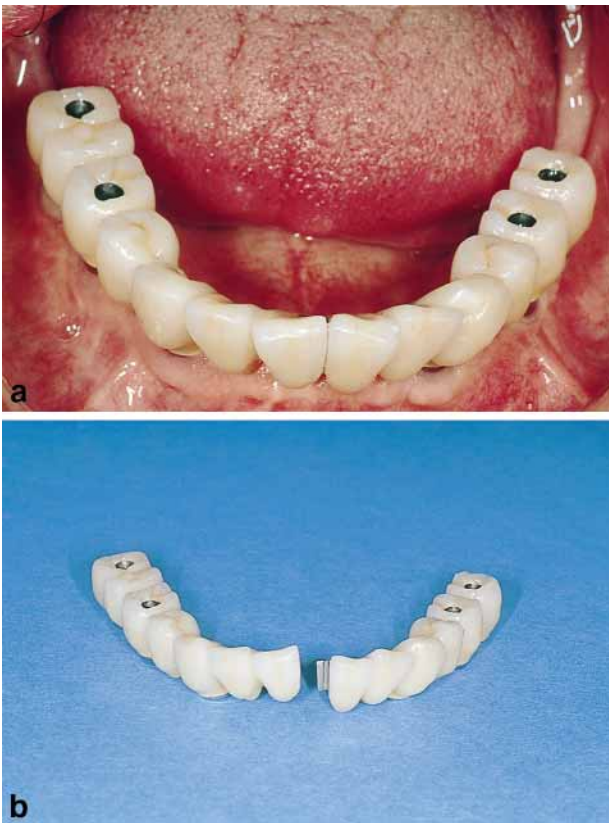

Fig. 7.19. a) Porcelain-to-gold fused bridgework, screw-retained (same case as Fig. 5a). Access holes for screw retention are visible. Bridgework shows optimum congruence of tooth and implant position. b) Bridgework is cast in two pieces and connected by a precision attachment, which provides resilience in vertical direction.



Tightening of screws

Fig. 7.20. Tightening of screws.

- 2 implants and mandibular overdentures: bars or single anchors for overdenture retention;
- >2 mandibular implants: rigid bar connector and overdenture;
- ≥ 4 mandibular implants: rigid bar or cantilever fixed prostheses;
- 4 to 6 maxillary implants: rigid bars with overdentures;
- 6 to 8 maxillary implants: full-arch fixed bridgework, segmentation possible.

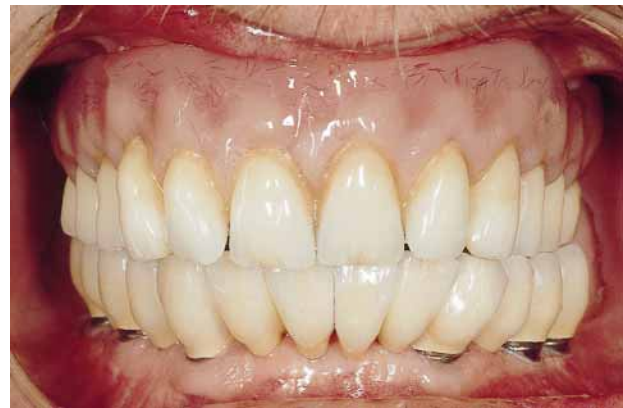

Fig. 7.21. Esthetic results. Maxillary overdenture supported by five implants matches esthetic appearance of fixed bridgework supported by six mandibular implants (same case as Figs 5a, 19a and b).

In Figs 7.18a–e, individually cast abutments mounted on six maxillary implants and cemented fixed bridgework are shown.

Figs 7.19a and b show fixed bridgework, screw-retained on six mandibular implants with an octa abutment. Fig. 7.20 gives an overview on the sequence of tightening of occlusal screws if a bar or a fixed prosthesis is mounted on multiple implants.

Indications for individual cast abutments include unacceptable access to the occlusal screw through the occlusal surface of the teeth or occlusal and cosmetic reasons. Individual cast abutments are preferred instead of prefabricated angulated abutments, and have the function of telescopes. Telescopes in conjunction with removable prostheses may be indicated if no space is available for mounting a bar.

Esthetics and compromised situations

While esthetic demands can easily be fulfilled in the edentulous mandible, the edentulous maxilla requires special attention. In implant dentistry, esthetics is a subject mostly related to the cosmetic appearance of fixed prostheses that replace missing teeth in the visible anterior zone. Removable prostheses are often regarded as a therapy of low quality, and esthetic aspects are rarely discussed. However, the rehabilitation of completely edentulous patients implies restoration of facial morphology and esthetics. This often requires removable prostheses with buccal denture flanges. Careful treatment planning in conjunction with individual prosthetic therapy may result in excellent esthetics of removable prostheses as well, as shown in Figs 7.21, 7.22a–c.

The problem of rehabilitation of facial esthetics and morphology is still more pronounced in com-

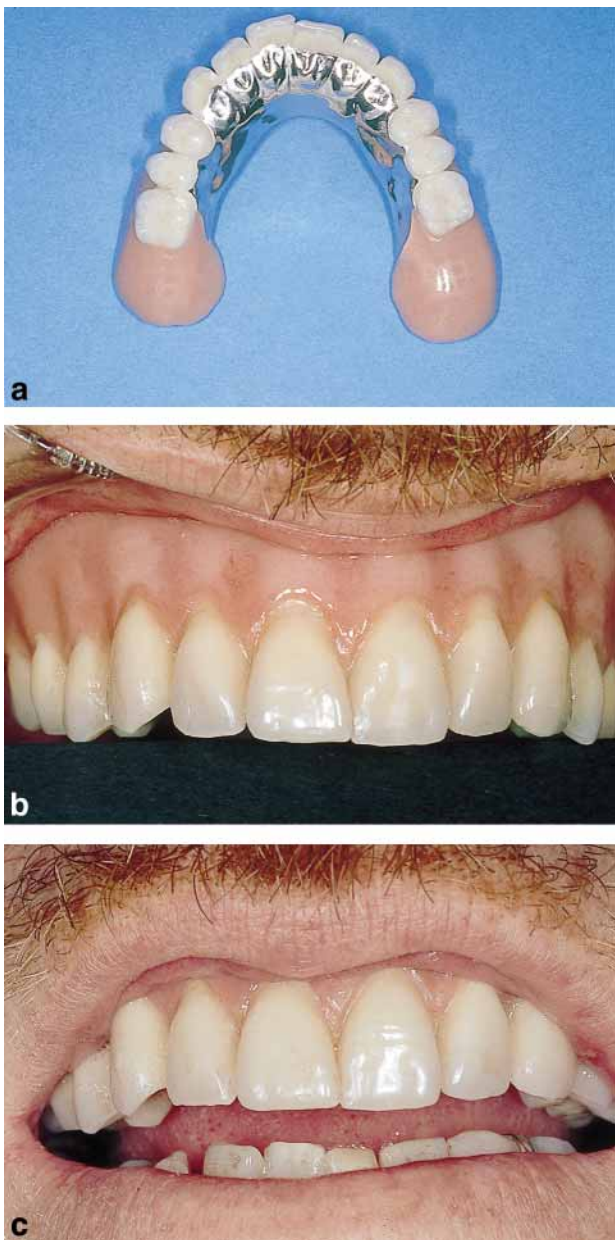


Fig. 7.22. Esthetic results. a) Maxillary overdenture with horseshoe design (same case as Figs 4, 11a and b). b) Excellent esthetics of front teeth and resin denture base. c) Patient displays “mucosa” when laughing.

promised situations. Compromised oral conditions such as acquired defects (trauma, malignant tumors) or congenital defects (cleft palate) may lead to full disability and the impossibility of wearing complete dentures (Mericske-Stern et al. 1999). This includes impairment of phonetics, chewing function and extra- and intraoral esthetics. Thus, placement of implants to support individually cast prostheses becomes highly important. In these situations, removable prostheses are often the better or only solution. Since size, extension and

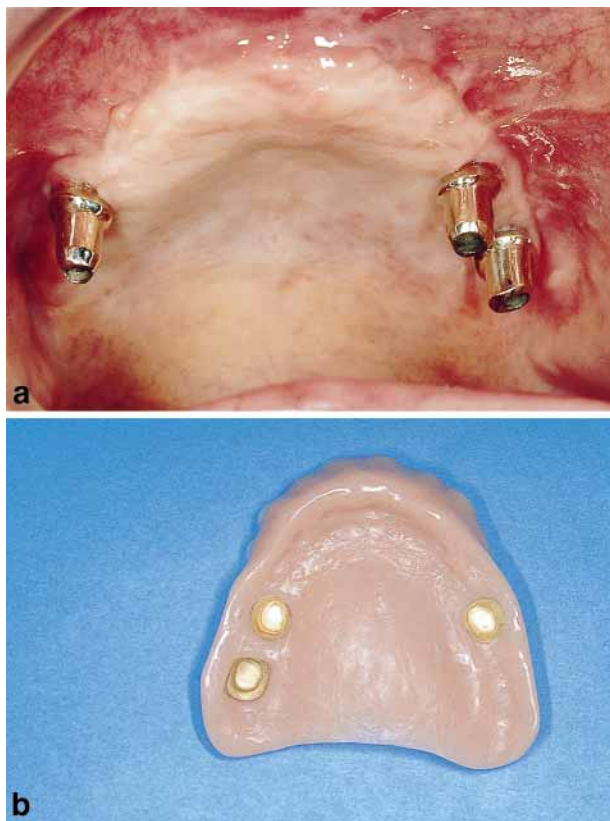


Fig. 7.23. Acquired defect. a) Patient who underwent multiple surgeries and is left with a completely flat maxillary jaw. Three implants are placed with individually cast telescopes. Distance is not adequate for a connecting bar. b) Complete denture with gold-galvano retainers.

morphology of defects are highly individual, each prosthesis is a masterpiece. Figs 7.23a and b, and 7.24a–c illustrate the esthetically demanding implant prosthodontic treatment in situations of compromised oral conditions.

Occlusion

There exist two basic principles of occlusion that apply to an occlusal scheme of either complete dentures (i.e. bilateral guidance and lingualized occlusion) or fixed prostheses (i.e. freedom in centric, with lateral guidance on the working side and no balancing contacts; the lateral guidance is a canine-protected guidance or a group function). These empirical occlusal schemes were originally developed for rehabilitation of complete edentulousness with complete dentures or natural teeth with fixed prostheses. They are adopted with minor modifications for implant prostheses.

In implant prosthodontics a specific evidence-based occlusal philosophy has not yet been developed. However, there are a few specific rules, which may favor optimum load distribution onto

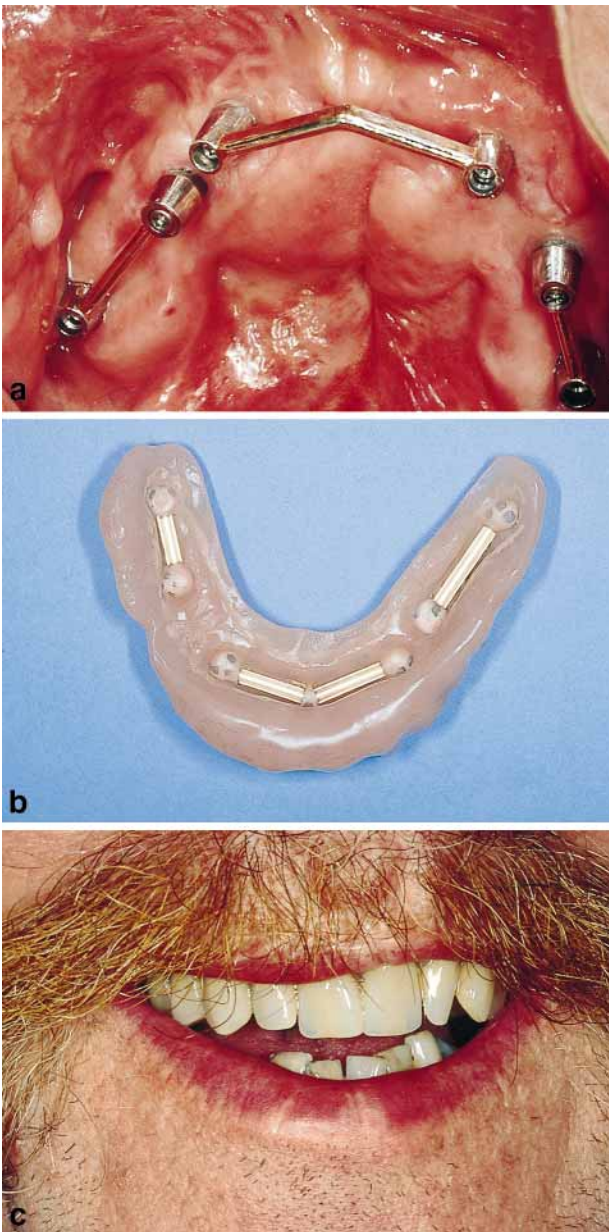


Fig. 7.24. Congenital defect. a) Patient with compromised situation of maxilla due to a cleft palate. Six implants with three bar segments are placed to support an overdenture. b) Inner surface of the maxillary overdenture with a bulky buccal flange is shown. c) Cosmetic appearance is highly satisfactory and matches characteristics of natural dentition in mandible.

the implants and ensure stability of the dentures. The greater the number of implants placed and the greater the rigidity of the prosthetic connection achieved, the more the occlusal scheme may resemble freedom in centric. From a biomechanical point of view, however, a balanced occlusal guidance as utilized with complete dentures might favor equilibration of occlusal loads due to simultaneous contacts on the working and non-working sides.

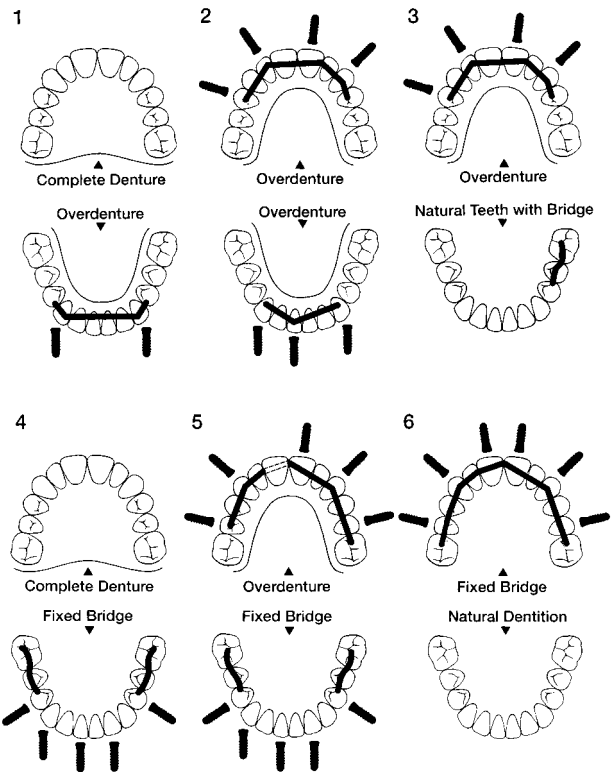


Fig. 7.25. 1) Bilaterally balanced occlusion. 2) Bilaterally balanced occlusion, biting on front teeth is possible. 3) Canine-protected guidance is possible, combination with front teeth guidance recommended. However, balancing contacts might contribute to higher stability of max. overdenture. 4) Bilaterally balanced occlusion is necessary for stabilizing max. complete denture. However, balancing contacts on cantilevers must be avoided. 5) Max. overdenture with long bars: balanced contacts may not be necessary. However, if balancing contacts are planned, these must be avoided on cantilevers. Group function may be recommended (combination of canine and premolar or front teeth). 6) Canine-protected guidance is possible. However, group function may be recommended to avoid overload of implant located in position 13 and 23.

Occlusal conception of complete dentures

Indications for a bilaterally balanced occlusion are a combination of mandibular overdentures supported by a few implants occluding with a complete denture in the opposing jaw, or mandibular overdentures occluding with maxillary overdentures. This type of balanced occlusion provides for primary stability of the dentures during functional loading. It also permits an even distribution of load between implants and denture-bearing tissues. The characteristics are:

- cusp-to-fossa contacts in centric occlusion;
- lingualized occlusion;
- bilateral guidance, i.e. simultaneous guidance on working and non-working sides.

Freedom in centric

Indications are multiple implants supporting bridgework and occluding with fixed prostheses or natural teeth. With fixed prostheses rigidly supported by multiple implants, the concept of freedom in centric can be applied unless a complete denture is worn in the opposing jaw. It is strongly suggested that the lateral guidance of the working side should not be exclusively on a single tooth or implant. While a canine-protected lateral guidance is easy for the technician to build up, a group function may have a better protective function for the implants and may distribute loading forces equally to the suprastructure. Balancing contacts as built up with complete dentures, although not prescribed with freedom in centric, may also contribute to load distribution, but they must be avoided on cantilevers. Examples are shown in Fig. 7.25.

- Canine-protected lateral guidance or group function;
- no balancing contacts on cantilevers;
- no guidance on single implants.

References

- Adell, R., Eriksson, B., Lekholm, U., Brånemark, P.I. & Jemt, T. (1990) A long-term follow-up of tissue-integrated implants in the treatment of the totally edentulous jaw. *International Journal of Oral & Maxillofacial Implants* **5**: 347–359.
- Albora, P. (1997) Tissue volume considerations in implant prosthodontics. *Journal of Prosthetic Dentistry* **77**: 492–496.
- Albrektsson, T. & Zarb, G.A. (1993) Current interpretations of the osseointegrated response. Clinical significance. *International Journal of Prosthodontics* **6**: 95–105.
- Albrektsson, T., Zarb, G., Worthington, P. & Eriksson, A.R. (1986) The long-term efficacy of currently used dental implants: a review and proposed criteria of success. *International Journal of Oral & Maxillofacial Implants* **1**: 11–25.
- Batenburg, R.H.K., van Oort, R.P., Reintsema, H., Brouwer, T.J., Raghoobar, G.M. & Boering, G. (1994) Overdentures supported by two IMZ implants in the lower jaw. A retrospective study of periimplant tissues. *Clinical Oral Implants Research* **5**: 207–212.
- Batenburg, R.H.K., Meijer, H.J.A., Raghoobar, G.M. & Vis-sink, A. (1998) Treatment concept for mandibular overdentures supported by endosseous implants: a literature review. *International Journal of Oral & Maxillofacial Implants* **13**: 539–545.
- Behneke, A., Behneke, N., d'Hoedt, B. & Wagner, W. (1997) Hard and soft tissue reactions to ITI screw implants: 3-year longitudinal results of a prospective study. *International Journal of Oral & Maxillofacial Implants* **12**: 749–757.
- Belser, U.C., Buser, D., Hess, D., Schmid, B., Bernard, J.P. & Lang, N.P. (1998) Aesthetic implant restorations in partially edentulous patients—a critical appraisal. *Periodontology* **2000** **17**: 132–150.
- Bergendal, T. & Enquist, B. (1998) Implant-supported overdentures, a longitudinal prospective study. *International Journal of Oral & Maxillofacial Implants* **13**: 253–262.
- Bryant, S.R. & Zarb, G.A. (1998) Osseointegration of oral implants in older and younger adults. *International Journal of Oral & Maxillofacial Implants* **13**: 492–499.
- Bürgin, W., Mericske-Stern, R. & Radics, P. (1998) 3-D *in vivo* force measurements on three mandibular implants supporting an overdenture. *Journal of Dental Research* **77**: 711, Abstr. No. 635, Special Issue B, 76th General Session of IADR.
- Buser, D., Weber, H.P., Brägger, U. & Balsiger, C.H. (1991) Tissue integration of one-stage ITI implants: 3-year results of a longitudinal study with hollow-cylinder and hollow-screw implants. *International Journal of Oral & Maxillofacial Implants* **6**: 405–412.
- Buser, D., Mericske-Stern, R., Bernard, J.P., Behneke, A., Behneke, N., Hirt, H.P., Belser, U.C. & Lang, N.P. (1997) Long-term evaluation of non-submerged ITI implants. Part 1: 8-year life table analysis of a prospective multi-center study with 2359 implants. *Clinical Oral Implants Research* **8**: 161–172.
- Buser, D., Mericske-Stern, R., Dula, K. & Lang, N.P. (1999) Clinical experience with one-stage, non-submerged dental implants. *Advances in Dental Research* **13**: 153–161.
- Cune, M.S., de Putter, C. & Hoogstraten, J. (1994) Treatment outcome with implant-retained overdentures. Part 1: Clinical findings and predictability of clinical treatment outcome. *Journal of Prosthetic Dentistry* **72**: 152–158.
- Hallmann, M. & Carlsson, B. (1996) Surgical correction of mal-positioned implants. A case report. *Clinical Oral Implants Research* **7**: 316–319.
- Hutton, J.E., Heath, R., Chai, J.Y., Harnett, J., Jemt, T., Johns, R.B., McKenna, S., McNamara, D.C., van Steenberghe, D., Taylor, R., Watson, R. & Herrmann, I. (1995) Factors related to success and failure rates at 3-year follow-up in a multicenter study of overdentures supported by Brånemark implants. *International Journal of Oral & Maxillofacial Implants* **10**: 33–42.
- Jemt, T. (1991) Failures and complications in 391 consecutively inserted fixed prostheses supported by Brånemark implants in edentulous jaws: a study of treatment from the time of prostheses placement to the first annual checkup. *International Journal of Oral & Maxillofacial Implants* **6**: 270–276.
- Jemt, T. (1993) Implant treatment in resorbed edentulous upper jaws. *Clinical Oral Implants Research* **4**: 187–194.
- Jemt, T. (1994) Fixed implant-supported prostheses in the edentulous maxilla. A five-year follow-up report. *Clinical Oral Implants Research* **5**: 142–147.
- Jemt, T., Book, K., Lie, A. & Börjesson, T. (1994) Mucosal topography around implants in edentulous upper jaws. Photogrammetric three-dimensional measurements of the effect of replacement of a removable prosthesis with a fixed prosthesis. *Clinical Oral Implants Research* **5**: 220–228.
- Jemt, T., Chai, J., Harnett, J., Heath, M.R., Hutton, J.E., Johns, R.B., McKenna, S., McNamara, D., van Steenberghe, D., Taylor, R., Watson, R.M. & Herrmann, I. (1996) A 5-year prospective multicenter follow-up report on overdentures supported by osseointegrated implants. *International Journal of Oral & Maxillofacial Implants* **11**: 291–298.
- Lundqvist, S., Lohmander-Agerskov, A. & Haraldson, T. (1992) Speech before and after treatment with bridges on osseointegrated implants in the edentulous upper jaw. *Clinical Oral Implants Research* **3**: 57–62.
- Mericske-Stern, R. (1990) Clinical evaluation of overdenture restorations supported by osseointegrated titanium implants. A retrospective study. *International Journal of Oral & Maxillofacial Implants* **5**: 375–383.
- Mericske-Stern, R. (1997) Force distribution on implants supporting overdentures: the effect of distal bar extensions. A 3-D *in vivo* study. *Clinical Oral Implants Research* **8**: 142–151.
- Mericske-Stern, R. (1998a) Treatment outcomes with implant-supported overdentures: clinical considerations. *Journal of Prosthetic Dentistry* **79**: 66–73.

- Mericske-Stern, R. (1998b) Three-dimensional force measurements with mandibular overdentures connected to implants by ball-shaped retentive anchors. A clinical study. *International Journal of Oral & Maxillofacial Implants* **13**: 36–43.
- Mericske-Stern, R. & Zarb, G.A. (1993) Overdentures: an alternative implant methodology for edentulous patients. *International Journal of Prosthodontics* **6**: 203–208.
- Mericske-Stern, R., Steinlin Schaffner, T., Marti, P. & Geering, A.H. (1994) Peri-implant mucosal aspects of ITI implants supporting overdentures. A five-year longitudinal study. *Clinical Oral Implants Research* **5**: 9–18.
- Mericske-Stern, R., Milani, O., Mericske, E. & Olah, A. (1995) Periotest measurements and osseointegration of mandibular ITI-implants supporting overdentures. A one-year longitudinal study. *Clinical Oral Implants Research* **6**: 73–82.
- Mericske-Stern, R., Assal, P. & Bürgin, W. (1996a) Simultaneous force measurements in 3 dimensions on oral endosseous implants *in vitro* and *in vivo*. A methodological study. *Clinical Oral Implants Research* **7**: 378–386.
- Mericske-Stern, R., Piotti, M. & Sirtes, G. (1996b) 3-D *in vivo* force measurements on mandibular implants supporting overdentures. A comparative study. *Clinical Oral Implants Research* **7**: 387–396.
- Mericske-Stern, R., Fährländer, F., Venetz, E., Geering, A.H. & Bürgin, W. (1998) 3-D force measurements *in vivo* on maxillary implants: comparison of a fixed prosthesis and a bar retained overdenture. *Journal of Dental Research* **77**: 1025, Abstr. No. 3145, Special Issue B, 76th General Session of IADR.
- Mericske-Stern, R., Perren, R. & Raveh, J. (1999) Life table analysis and clinical evaluation of oral implants supporting prostheses after resection of malignant tumors. *International Journal of Oral & Maxillofacial Implants* **14**: 673–680.
- Mombelli, A. & Mericske-Stern, R. (1990) Microbiological features of stable osseointegrated implants used as abutments for overdentures. *Clinical Oral Implants Research* **1**: 1–7.
- Palmqvist, S., Sondell, K. & Swartz, B. (1994) Implant-supported maxillary overdentures: outcome in planned and emergency cases. *International Journal of Oral & Maxillofacial Implants* **9**: 184–190.
- Palmqvist, S., Sondell, K., Swartz, B. & Svenson, B. (1996) Marginal bone levels around maxillary implants supporting overdentures or fixed prostheses: a comparative study using detailed narrow-beam radiographs. *International Journal of Oral & Maxillofacial Implants* **11**: 223–227.
- Quirynen, M., Naert, I., van Steenberghe, D. & Nys, L. (1992) A study of 589 consecutive implants supporting complete fixed prostheses. Part I: Periodontal aspects. *Journal of Prosthetic Dentistry* **68**: 655–663.
- Roos, J., Sennerby, L., Lekholm, U., Jemt, T., Gröndahl, K., Albrektsson, T. (1997) A qualitative and quantitative method for evaluating implant success: a 5-year retrospective analysis of the Brånemark implant. *International Journal of Oral & Maxillofacial Implants* **12**: 504–514.
- Salama, H., Salama, M. & Garber, D.A. (1995) Techniques for developing optimal peri-implant papillae within the esthetic zone. I. Guided soft tissue augmentation: the three-stage approach. *Journal of Esthetic Dentistry* **7**: 3–9.
- Smith, D. & Zarb, G.A. (1989) Criteria for success of osseointegrated endosseous implants. *Journal of Prosthetic Dentistry* **62**: 567–572.
- Spiekermann, H., Jansen, V.K. & Richter, E.J. (1995) A 10-year follow-up study of IMZ and TPS implants in the edentulous mandible using bar-retained overdentures. *International Journal of Oral & Maxillofacial Implants* **10**: 231–243.
- Widmark, G., Andersson, B., Andrup, B., Carlsson, G.E., Ivanoff, C.J. & Lindvall, A.M. (1998) Rehabilitation of patients with severely resorbed maxillae by means of implants with or without bone grafts. A 1-year follow-up study. *International Journal of Oral & Maxillofacial Implants* **13**: 474–482.
- Wismeyer, D., van Waas, A.J. & Vermeeren, J.I.J.F. (1995) Overdentures supported by ITI implants: a 6.5-year evaluation of patient satisfaction and prosthetic aftercare. *International Journal of Oral & Maxillofacial Implants* **10**: 744–749.
- Zarb, G.A. & Schmitt, A. (1989) The longitudinal clinical effectiveness of osseointegrated implants. The Toronto study. Part I: Surgical results. *Journal of Prosthetic Dentistry* **62**: 451–470.
- Zarb, G.A. & Schmitt, A. (1990a) The longitudinal clinical effectiveness of osseointegrated dental implants: The Toronto study. Part II: The prosthetic results. *Journal of Prosthetic Dentistry* **64**: 53–61.
- Zarb, G.A. & Schmitt, A. (1990b) The longitudinal clinical effectiveness of osseointegrated implants. The Toronto study. Part III: Problems and complications encountered. *Journal of Prosthetic Dentistry* **64**: 185–194.
- Zarb, G.A. & Schmitt, A. (1994) Osseointegration for elderly patients: The Toronto study. *Journal of Prosthetic Dentistry* **72**: 559–568.
- Zarb, G.A. & Schmitt, A. (1995) Implant prosthodontic treatment options for the edentulous patients. *Journal of Oral Rehabilitation* **22**: 661–671.