

# Chronic Therapy-Resistant Neck Pain in a Fifty-Year-Old Man: The Role of Partially Impacted Third Molars – Case Report and New Pathophysiological Insights

Lucy Naomi Shiratori Tusita<sup>a</sup> Lorenz Fischer<sup>b</sup>

<sup>a</sup>Doctor of Dental Surgery DDS, Private clinic, Sao Paulo, Brazil; <sup>b</sup>Neural therapy, General Internal Medicine, University of Bern, Bern, Switzerland

## Keywords

Neural therapy · Teeth · Trigeminal nerve · Local anesthetics · Neck pain

## Abstract

**Background:** Inflammatory and mechanical stimuli in tooth/jaw pathologies can have far-reaching consequences via trigeminal and autonomic circuitry and can cause systemic (e.g., autoimmune) diseases and pain conditions outside the tooth/jaw region. In addition to a case report, we also describe new pathophysiological findings. **Case Report:** We report on a patient with chronic, therapy-resistant neck pain whose cause lied in the tooth/jaw region, specifically, in wisdom teeth with space problems, and partially impacted. The tooth/jaw area itself was not painful; however, neck pain developed via the nucleus spinalis n. trigemini which extends into the cervical medulla. Surgical restoration of the wisdom teeth and subsequent neural therapy treatment of the extraction scars provided permanent pain relief. **Conclusion:** In case of therapy-resistant neck pain (among others), it is worthwhile to look for pathologies in the dental/jaw area, possibly allowing for a causal therapy.

© 2023 The Author(s).  
Published by S. Karger AG, Basel

**Chronische therapieresistente Nackenschmerzen bei einem fünfzigjährigen Mann. Die Rolle von teilimpaktierten 3. Molaren. Kasuistik und neue pathophysiologische Erkenntnisse**

## Schlüsselwörter

Neuraltherapie · Zähne · Nervus trigeminus · Lokalanästhetika · Nackenschmerzen

## Zusammenfassung

**Hintergrund:** Entzündliche und mechanische Pathologien im Zahn-Kieferbereich können über trigeminale Verschaltungen weitreichende Folgen haben und zu systemischen (z.B. autoimmunen) Erkrankungen und zu Schmerzzuständen ausserhalb des Zahn-Kieferbereiches führen. Neben einem Fallbericht beschreiben wir auch neue pathophysiologische Erkenntnisse. **Fallbericht:** Wir berichten über einen Patienten mit chronischen therapieresistenten Nackenschmerzen, bei dem die Ursache im Zahn-Kieferbereich lag. Es handelte sich um Weisheitszähne mit Platzproblemen, zum Teil impaktiert. Der Zahn-Kieferbereich selbst war nicht schmerzhaft, aber über den Nucleus spinalis n. trigemini, der bis ins Halsmark reicht, sind Nackenschmerzen entstanden. Die chirurgische Sanierung der Weisheitszähne und die spätere neuraltherapeutische Behandlung der Extraktionsnarben brachten eine dauerhafte Schmerzfreiheit.

**Schlussfolgerung:** Bei therapieresistenten Nackenschmerzen (u.a.) lohnt es sich, im Zahn-Kieferbereich nach Pathologien zu suchen. Damit kann eine kausale Therapie ermöglicht werden.

© 2023 The Author(s).  
Published by S. Karger AG, Basel

## Introduction

The importance of oral health for systemic health has been pointed out for more than a hundred years [1]; however, it used to be an idea rather than a field of research. Nowadays, luckily, the dentist's role in general health has become increasingly clear [2]. Patients with poor oral hygiene, measured by plaque index, have a higher risk of developing autoimmune diseases [3].

Periodontal disease significantly increases the prevalence and incidence of coronary heart disease [4, 5] and also the risk of preterm birth [6] and low birth weight [7]. Experiences in neural therapy (diagnostic and therapeutic applications of local anesthetics [LAs]) [8] showed that inflammatory and mechanical problems in the teeth/jaw region can lead to referred pain or systemic illnesses [8–12].

In dental practice, third molars (3 M) get special attention because they often remain included/semi-included or poorly positioned [13, 14]. This is often due to problems of lack of space in the mandible or maxilla, leading to bacterial plaque, which promotes the occurrence of localized inflammation such as gingivitis, pericoronitis, and cavities [14].

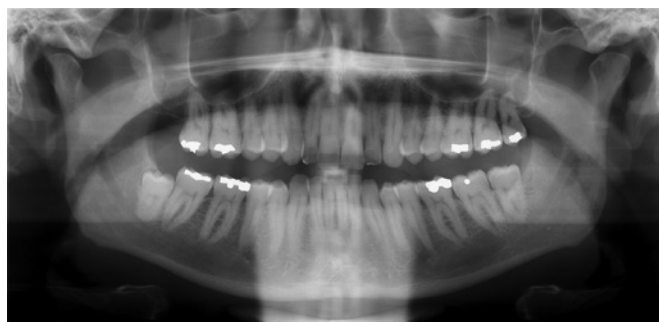However, impacted and/or chronically inflamed 3 M can be locally asymptomatic, but that does not mean they are always disease free. There may be chronic inflammatory processes and silent pathologies in the teeth affecting systemic health [15].

3 M pathologies are also perceived by the nervous system [9–12, 16]. The teeth are connected to the nervous system via the trigeminal nerve (in addition to sympathetic fibers). Its sensory input stimulates the trigeminal nucleus. For our case report, we paid special attention to the spinal part of the trigeminal nucleus (nucleus spinalis nervi trigemini [NSNT]) and discussed new pathophysiological aspects.

## Case Report

### History

We report on a fifty-year-old man who had been suffering from increasing neck pain, burning, and stinging since he was 18 years old. Rotation of the cervical spine to the left or right increased the pain up to a peak level of 6 on the Visual Analog Scale (VAS). Sitting (at the computer) was worst.



**Fig. 1.** Orthopantomogram. The left mandibular ascending ramus is very close to the erupted teeth 2.8 and 3.8. The lack of space around the two teeth could originate gingival chronic inflammation because of difficult daily oral care. The close vicinity between semi-included tooth 4.8 and the mandibular ramus of the trigeminal nerve can generate sensory input to the nervous system by mechanical pressure, and its partial eruption can generate a chronic gingival inflammation.

The patient had been given chiropractic therapy, physiotherapy, and non-steroidal anti-inflammatories (diclofenac) without success. There was no other illness known, and he did not take any other medication. In this situation, the patient was referred to our pain center by his family doctor.

### Findings

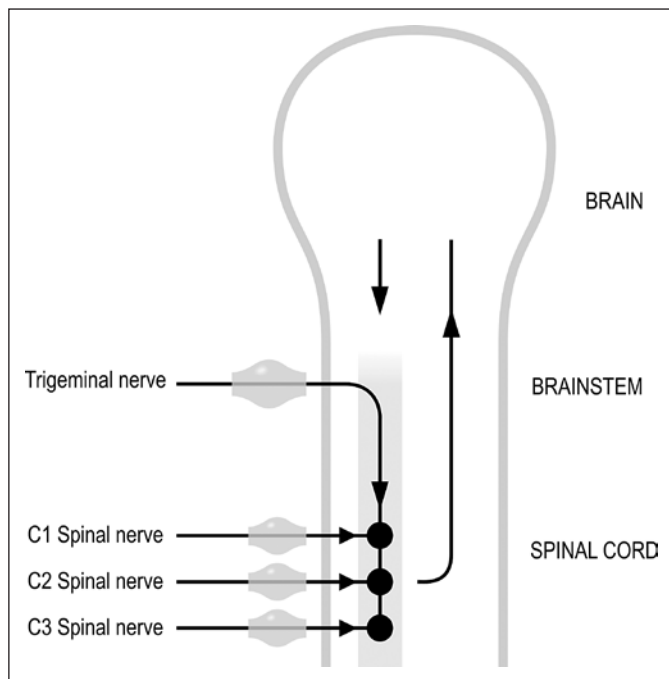
All movements of the cervical spine were limited between 10 and 30°, and at the maximum of the movements, the pain increased. The muscles were in higher tension (especially the levator scapulae and the splenius capitis muscle on both sides). We also found myofascial trigger points in these muscles on both sides. Clinical neurological findings were symmetrical and in order.

The X-ray showed a light generalized spondylosis and spondylarthrosis as well as a light chondrosis C5/C6 (that could not explain his pain). Laboratory findings showed no signs of a general inflammation or of any disease.

### Therapeutic Intervention and Further Course

In the first session, we treated the myofascial trigger points and the increased tonus of the muscles mentioned with a well-directed injection of LA procaine 1% (according to neural therapy). These local interventions were not successful. As a routine in such cases, we ordered an orthopantomogram of the teeth, although the patient had no tooth pain. We found 3 M with a space problem at positions 2.8 and 3.8 (ascending mandibular ramus), and an impacted tooth with perifocal inflammation at 4.8 (Fig. 1). As a diagnostic test (with the question of an influence on the neck pain, see Discussion), we infiltrated the periodontal tissue of these three teeth with LA procaine 1%. Minutes after these interventions, the patient was nearly free of pain in the neck for the first time since many years. After 1 week, the pain in the neck appeared again, reaching the same level.

With this “positive” test, we made the indication for extraction of the teeth 2.8, 3.8, and 4.8. Afterward, the patient was nearly pain free in the neck. Half a year later, his neck pain appeared again to a slight degree (VAS 2–3). Subsequently, we infiltrated the scars of the teeth extractions with procaine 1% in the regions 2.8, 3.8, and 4.8. After this last intervention, the patient was pain free, and he showed almost normal mobility of the cervical spine without increased muscle tone. The freedom from neck pain has lasted for over 3 years.



**Fig. 2.** Convergence of afferents. Some fibers of the trigeminal nerve extend in the NSNT into the upper cervical medulla and form a convergence with the afferents of spinal nerves.

## Discussion

All local therapies in the pain area of the neck had failed. This made us think of a cause outside the pain area. Based on clinical experience in neural therapy, the cervical region has a relationship with the tooth region [9, 17, 18]. These regions are connected by the trigeminal nerve, namely, its nucleus spinalis [10, 19, 20]. Therefore, chronic irritations such as impacted and displaced 3 M as in our patient can lead to neck pain, even if the tooth region itself may be asymptomatic. Thus, the individual causal therapy for the neck in our case was the surgical elimination of the odontogenic disturbances.

However, as mentioned, 6 months after the extraction, milder neck pain reappeared. How can this be explained? Scars sometimes may become “interference fields” [8], also called “neuromodulatory triggers” [16] over time. Scar tissue contains collagen fibers; they behave similar to electrical dipoles [21], and if mechanically stimulated, they may generate action potentials that are transmitted centrally [22] via the trigeminal nerve. Another possibility for action potentials to appear is the ectopic type emerging from neuromas in the scar tissue [22]. Even efferent sympathetic fibers can play a role in activating scars or nerves [23] by coupling mechanisms [24]. From a pathophysiological point of view, we believe that the infiltration of procaine 1% into the extraction scars could

break the vicious cycle and induce a “reset” [25] so that the patient was finally relieved of his neck symptoms.

We would like to list here some other facts that further help understand what happened to our patient. In the trigeminal sensory nucleus, which is localized in the brainstem and upper cervical medulla (NSNT), there is a convergence of afferents from different cranial nerves (VII, IX, and X) as well as from the upper cervical nerves [10, 17, 18, 26–28]. The functional structure of the NSNT in the upper cervical medulla corresponds in principle to that of the columna posterior [27]. The NSNT can even be understood as a continuation of the posterior to the cranial column: The nociceptive afferents of the spinal nerves leading into the posterior column of the upper cervical segments intermingle with those of the NSNT (Fig. 2, 3). There are different names for this fact such as “trigemino-cervical complex” [20] and “nucleus paratrigeminalis” [29].

Of interest are experiments which showed that it is possible to activate motor neurons in the neck via electrical stimulation of the trigeminal nerve in humans [30] and in animal experiments [31]. The influence of the direct connection between teeth and trigeminal nerve and its nucleus spinalis had already been shown in cat experiments: dental pulp was removed from healthy cats, and after some days, a degeneration of neurons was detected in the NSNT [32].

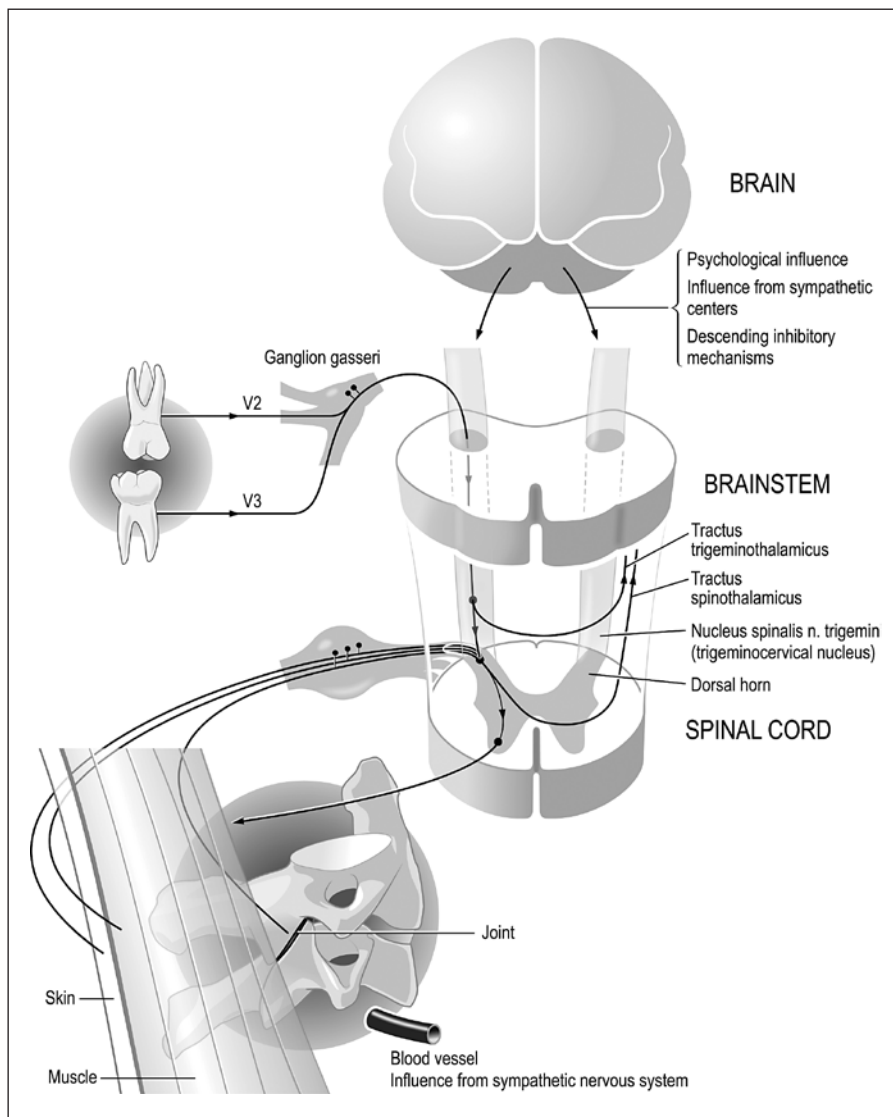
The sympathetic nervous system is involved in pain events [24], including processes in the trigemino-cervical complex [27]. Also of interest is the supply of sympathetic fibers to the dentin and the pulp [33] which connect the teeth with the whole autonomic nervous system, which in turn can influence all organ systems of the body [9, 10, 16, 25].

## Conclusion

In patients with refractory neck pain, it is worthwhile to look not only for degenerative findings obtained in imaging (which played no role in our patient’s pain) but also for possible chronic irritations in the trigeminal area. Such irritations of the trigeminal nerve can originate, e.g., from the tooth/jaw area, even if there is no pain there. Thus, it is important for a successful treatment to distinguish between “the site (i.e., where the patient feels the pain) and the source of pain” [34].

Functional anatomy and modern neurophysiology are increasingly leading us to a holistic view [10, 16, 25]. Newman [2] put the importance of teeth for the whole organism aptly: “This is about a rediscovery, not a discovery. I wonder why it has taken so long to be accepted—and not unanimously, I would guess—that oral health is so important in relation to systemic health that the dentist has a responsibility for general health.”

**Fig. 3.** Illustration of the neuroanatomy relevant to the case report. Due to the convergence of the afferents as described in Fig. 2, it is evident here that in the upper cervical medulla, there is a correspondence or fusion between the NSNT and the column of the head of the posterior horn. It becomes understandable how pathologies of the teeth can influence the muscular and articular structures of the cervical spine (pain, tension, blockage). These processes are amplified by feedback mechanisms via brainstem and brain. In parallel, the sympathetic nervous system can also have an effect on pain, inflammation, and micro-circulation.



### Acknowledgments

We thank Sabina M. Ludin for professional and technical assistance, Hans Holzherr for the artwork, and Hans Barop for his critical review of the manuscript.

### Statement of Ethics

Written informed consent was obtained from the patient for publication of this case report and any accompanying images.

### Conflict of Interest Statement

The authors have no conflicts of interest to declare.

### Funding Sources

This research did not receive any grant.

### Author Contributions

Authors contributed equally.

### Data Availability Statement

All data generated or analyzed during this case report are included in this article. Further inquiries can be directed to the corresponding author.

## References

- 1 Miller WD. The human mouth as a focus of infection. *The Lancet*. 1891;138(3546):340–2.
- 2 Newman HN. Focal infection. *J Dent Res*. 1996 Dec;75(12):1912–9.
- 3 Julkunen A, Heikkinen AM, Söder B, Söder PÖ, Toppila-Salmi S, Meurman JH. Autoimmune diseases and oral health: 30-year follow-up of a Swedish cohort. *Dent J*. 2017 Dec 22;6(1):1.
- 4 Bahekar AA, Singh S, Saha S, Molnar J, Arora R. The prevalence and incidence of coronary heart disease is significantly increased in periodontitis: a meta-analysis. *Am Heart J*. 2007 Nov;154(5):830–7.
- 5 Rydén L, Buhlin K, Ekstrand E, de Faire U, Gustafsson A, Holmer J, et al. Periodontitis increases the risk of a first myocardial infarction: a report from the PAROKRANK study. *Circulation*. 2016 Feb 9;133(6):576–83.
- 6 Manrique-Corredor EJ, Orozco-Beltran D, Lopez-Pineda A, Quesada JA, Gil-Guillen VF, Carratala-Munuera C. Maternal periodontitis and preterm birth: systematic review and meta-analysis. *Community Dent Oral Epidemiol*. 2019 Jun;47(3):243–51.
- 7 Khader YS, Ta'ani Q. Periodontal diseases and the risk of preterm birth and low birth weight: a meta-analysis. *J Periodontol*. 2005 Feb;76(2):161–5.
- 8 Huneke F. Neuraltherapie, Sekundenphänomen und Chirurgie. *Therapiewoche*. 1955;5: 286–94.
- 9 Adler E. *Störfeld und Herd im Trigeminusbereich*. 4th ed. Heidelberg: Verlag für Medizin Dr. E. Fischer; 1990.
- 10 Barop H. *Textbook and atlas of neural therapy. Diagnosis and therapy with local anesthetics*. Stuttgart: Thieme; 2018.
- 11 Fischer L. *Neuraltherapie: neurophysiologie, injektionstechnik, therapievorschläge*. 5th ed. Stuttgart: Thieme; 2019.
- 12 Weinschenk S, editor 2nd ed. *Handbuch neuraltherapie*. Stuttgart: Thieme; 2020.
- 13 Blakey GH, Jacks MT, Offenbacher S, Nance PE, Phillips C, Haug RH, et al. Progression of periodontal disease in the second/third molar region in subjects with asymptomatic third molars. *J Oral Maxillofac Surg*. 2006 Feb; 64(2):189–93.
- 14 Campbell JH. Pathology associated with the third molar. *Oral Maxillofac Surg Clin North Am*. 2013 Feb;25(1):1–10.
- 15 Offenbacher S, Beck JD, Moss KL, Barros S, Mendoza L, White RP Jr. What are the local and systemic implications of third molar retention? *J Oral Maxillofac Surg*. 2012 Sep;70(9 Suppl 1):S58–65.
- 16 Engel R, Barop H, Giebel J, Ludin SM, Fischer L. The influence of modern neurophysiology on the previous definitions of “segment” and “interference field” in neural therapy. *Complement Med Res*. 2022;29(3):257–67.
- 17 Schmidt M, Hennke T, Knöchel M, Kürten A, Hierholzer J, Daniel P, et al. Can chronic irritations of the trigeminal nerve cause musculoskeletal disorders? *Forsch Komplementmed*. 2010;17(3):149–53.
- 18 Torisu T, Tanaka M, Murata H, Wang K, Arndt-Nielsen L, De Laat A, et al. Modulation of neck muscle activity induced by intra-oral stimulation in humans. *Clin Neurophysiol*. 2014 May;125(5):1006–11.
- 19 Clara M. *Das Nervensystem des Menschen*. 3rd ed. Leipzig: Barth; 1959.
- 20 Bartsch T, Goadsby PJ. The trigeminocervical complex and migraine: current concepts and synthesis. *Curr Pain Headache Rep*. 2003 Oct; 7(5):371–6.
- 21 Athenstaedt H. Pyroelectric and piezoelectric properties of vertebrates. *Ann N Y Acad Sci*. 1974;238:68–94.
- 22 Fischer L, Ludin SM, Puente de la Vega K, Sturzenegger M. Neuralgia of the glossopharyngeal nerve in a patient with posttonsillectomy scarring: recovery after local infiltration of procaine—case report and pathophysiologic discussion. *Case Rep Neurol Med*. 2015;2015: 560546.
- 23 Michels T, Ahmadi S, Michels D. Physiologisch-anatomische Aspekte in der Neuraltherapie. Behandlungsergebnisse akuter und chronischer Schmerzen. *Deutsche Zeitschrift für Akupunktur*. 2011;54(2):6–9.
- 24 Jänig W, Baron R. Pathophysiologie des Schmerzes. In: Fischer L, Peucker E, editors. *Lehrbuch integrative schmerztherapie*. Stuttgart: Haug; 2011. p. 35–71.
- 25 Fischer L, Barop H, Ludin SM, Schaible HG. Regulation of reflexory hyperinflammation in viral and other diseases by means of stellate ganglion block. A conceptual view with a focus on Covid-19. *Auton Neurosci*. 2022 Jan; 237:1102903.
- 26 Hülse M, Neuhuber W, Wolff HD. *Die obere Halswirbelsäule: pathophysiologie und Klinik*. Berlin, Heidelberg: Springer; 2005. p. 55–71.
- 27 Neuhuber WL. Funktionelle Neuroanatomie des kraniozervikalen Übergangs. In: Hülse M, Neuhuber W, Wolff HD, editors. *Die obere Halswirbelsäule. Pathophysiologie und Klinik*. Heidelberg: Springer; 2005. p. 55–71.
- 28 Weinschenk S, Hollmann MW, Göllner R, Picardi S, Strowitzki T, Diehl L, et al. Injections of local anesthetics into the pharyngeal region reduce trapezius muscle tenderness. *Forsch Komplementmed*. 2016;23(2):111–6.
- 29 Caous CA, de Sousa Buck H, Lindsey CJ. Neuronal connections of the paratrigeminal nucleus: a topographic analysis of neurons projecting to bulbar, pontine and thalamic nuclei related to cardiovascular, respiratory and sensory functions. *Auton Neurosci*. 2001 Dec 10; 94(1–2):14–24.
- 30 Leandri M, Gottlieb A, Cruccu G. Head extensor reflex evoked by trigeminal stimulation in humans. *Clin Neurophysiol*. 2001; 112(10):1828–32.
- 31 Zeredo JL, Toda K, Soma K. Nature of neck motor unit activities evoked by different trigeminal inputs in rats. *J Dent Res*. 2003;82(5): 402–5.
- 32 Westrum LE, Canfield RC, Black RG. Transganglionic degeneration in the spinal trigeminal nucleus following removal of tooth pulps in adult cats. *Brain Res*. 1976 Jan 9;101(1): 137–40.
- 33 Ommerborn M, Raab W. Odontalgie. In: Hugger A, Göbel H, Schilgen M, editors. *Gesichts- und Kopfschmerzen aus interdisziplinärer Sicht*. Heidelberg: Springer; 2006. p. 51–63.
- 34 Okeson JP. *Orofacial pains. The clinical management of orofacial pain*. 6th ed. Chicago, Berlin, Tokyo, Copenhagen: Quintessence publishing Co, Inc; 2005.